

# The Outcome of Endonasal Endoscopic Versus Transcanalicular Laser Dacryocystorhinostomy

Amber Khalid<sup>1\*</sup>, Sharjeel Sultan<sup>1</sup>, Mahtab Alam Khanzada<sup>2</sup>, Muhammad Wasif<sup>3</sup>,  
Ayoob Bhatti<sup>1</sup>, Aveen Fatima<sup>1</sup>

## ABSTRACT

**OBJECTIVE:** The purpose of our research was to analyze and compare the outcome of Endonasal Endoscopic (EE-DCR) versus Endoscopic Trans-canalicular Laser assisted Dacryocystorhinostomy (TC-DCR) for the treatment of Dacryocystitis

**METHODOLOGY:** This study was a non-randomized control trial executed by the Department of Ophthalmology in collaboration with the Otorhinolaryngology (ENT) department at Ziauddin University Hospital Karachi. The study spanned two years, from August 2021 to July 2023. All patients were selected based on inclusion criteria, presented with complaints of epiphora in the ophthalmology department, and were assessed clinically by an ophthalmologist and ENT surgeon. The data was compiled in SPSS 23, and comparative data was analyzed using a chi-square test.

**RESULTS:** In this research, we analyzed and compared the functional and anatomical outcomes of EE-DCR versus TC-DCR. The mean age of participants was  $39.4 \pm 2.3$  years in both groups. In the EE-DCR group, there were 15 men (26.3%) and 42 women (73.7%), while in the TC-DCR group, there were 13 men (22.5%) and 27 women (67.5%). The outcome for TC-DCR was successful in 90% of cases, slightly higher than 84.2% for EE-DCR.

**CONCLUSION:** TC-DCR is considered a better surgical approach than EE-DCR because it is minimally invasive, safe and less time-consuming. The outcome of both procedures was assessed postoperatively in terms of functional and anatomical success rate, and TC-DCR showed slightly better results.

**KEYWORDS:** Endonasal Endoscopic DCR, Transcanalicular Laser assisted DCR, Chronic Dacryocystitis, Nasolacrimal duct obstruction, Acute Dacryocystitis, Probing and syringing.

## INTRODUCTION

Nasolacrimal duct obstruction (NLD) is a primary cause of epiphora, often managed through a surgical procedure called Dacryocystorhinostomy (DCR). NLD obstruction can be attributed to a variety of etiological factors. These factors encompass various causes, including inflammation, scarring, tumor and age-related mucosal thickening of NLD<sup>1</sup>. Tears normally drain from the canaliculi to the inferior meatus of the nose. In this procedure, we create an alternative pathway between the canaliculi and nose through the ostium to bypass any obstruction of NLD<sup>2</sup>.

DCR is recommended only when conservative treatments, including topical and systemic antibiotics and probing syringing, have proven ineffective in resolving the blockage<sup>3</sup>. Various surgical techniques, including internal and external approaches, can

perform DCR. External DCR is a traditional gold standard technique; the surgeon gives a curvilinear incision 10-12 mm in length and 3-4 mm away from the medial canthus near the lacrimal sac, and a small piece of lacrimal bone is removed to make an ostium. The skin incision was secured with 6-0 silk. The major drawback of external DCR is visible scarring, which causes serious cosmetic effects<sup>4</sup>. Compared to the external approach, internal DCR is minimally invasive, has a short duration of surgery, is early rehabilitation, and has a low complication rate. Surgeons can perform Endoscopic DCR through endonasal or transcanalicular approach. In EE-DCR, the primary objective of the surgeon is to create an alternative pathway between the lacrimal canaliculi and the nose using a nasal approach with the assistance of an endoscope. The ostium is made through the nose; the DCR tube is inserted through the canaliculi and secured in the nose<sup>5</sup>. The TC-DCR is another type of internal DCR in which a thin probe is inserted through the canaliculi, and a diode laser is used through the canaliculi to create an ostium. An endoscope is used to assess the nose and ostium size. This procedure is less invasive than EE-DCR<sup>6</sup>. The internal DCR offers a more cosmetically pleasing outcome and is suitable for individuals concerned about external scarring or seeking quicker post-operative recovery<sup>7</sup>. The

<sup>1</sup>Department of Ophthalmology, Ziauddin University, Karachi, Sindh-Pakistan.

<sup>2</sup>Institute of Ophthalmology, Liaquat University of Medical & Health Sciences, Jamshoro, Sindh-Pakistan.

<sup>3</sup>Department of ENT Head & Neck Surgery, Ziauddin University, Karachi, Sindh-Pakistan.

**Correspondence:** dr.arain@gmail.com

doi: 10.22442/jlumhs.2024.01078

Received: 11-10-2023

Revised: 14-03-2024

Accepted: 22-03-2024

Published Online: 23-05-2024



functional outcome of DCR ranges from 70% to 90% for both internal and external approaches<sup>8</sup>. Several factors can impact the result of the surgical approach, including the cause and severity of nasolacrimal duct obstruction and any anatomical anomalies or scarring<sup>9</sup>. Besides these factors, the surgeon's expertise and experience play a significant role<sup>10</sup>.

Our research aims to assess and correlate the effectiveness, safety, and outcomes of Endonasal Endoscopic (EE-DCR) versus transcanalicular diode laser (TC-DCR) for treating nasolacrimal duct obstruction. Our study will provide valuable insight into each approach's suitability based on a particular patient or clinical scenario.

## METHODOLOGY

Our research was a non-randomized controlled trial carried out in the Department of Ophthalmology with the collaboration of the Otorhinolaryngology (ENT) department at Ziauddin University Hospital in Karachi. The study spanned two years, from August 2021 to July 2023. Before commencing the research, we obtained approval from the institutional ethical committee. A total of 97 eyes of 85 patients who met the inclusion criteria were included in the study. The inclusion criteria were age 18-60 years, NLD blockage confirmed on probing and syringing, regurgitation test positive and previous failed external DCR. Exclusion criteria include trauma, failed EE-DCR, failed TC-DCR, Nasal polyp, and deviated nasal septum. All diagnosed cases of Dacryocystitis were assessed clinically by an ophthalmologist, and relevant investigations were performed where indicated, such as dacryocystography. Subsequently, all patients were referred to the ENT department to rule out any deformity or cause related to the nose. After assessment, patients were assigned into the group: Group 1, selected for EE-DCR, comprised 57 patients, and Group 2, comprised 40 patients for TC-DCR. Written Informed consent was taken, and brief information was given regarding the surgical procedure. The surgeries were performed with an ophthalmologist and ENT surgeon under general anesthesia.

The nasal mucosa was infiltrated in both groups with a solution containing 1:100,000 adrenaline and 2% Lidocaine. In EE-DCR, the endoscope analyzed the nasal cavity and nasal mucosa adjacent to the lacrimal sac, which was incised vertically and elevated. The nasal mucosa is removed with endoscopic forceps. The lacrimal bone was excised with Kerrison rongeurs, and ostium was established. After removing the bone, the lacrimal sac was exposed and incised with the blade. A silicon tube was passed through the upper and lower punctum and secured into the nasal cavity. In TC-DCR, the lacrimal sac was assessed using the punctum. A thin fiber optic probe examined the lacrimal sac and

lacrimal bone. The diode laser was employed to create an ostium, and an endonasal endoscope was used to assess the nose. The silicon tube was inserted through the punctum.

The nasal packing was postoperatively applied for 24 hours in both approaches. All patients were prescribed oral antibiotics and analgesics twice daily for five days. Additionally, topical antibiotic eye drops, nasal decongestant, and normal saline nasal drops were administered 4-5 times for two weeks postoperatively. Follow-up appointments were scheduled for the 1st post-operative day, followed by visits at the 1st week, 4th week, 12th week, 24th week, and 48th week post-surgery. The silicone tube was removed at the end of the third month. During each follow-up appointment, patients underwent an examination by an ophthalmologist and an ENT surgeon to assess the anatomical and functional outcomes of the surgery. Anatomical outcomes were evaluated by probing and syringing at the 1st, 3rd, and 6th months to evaluate the patency of the NLD, and ostium size was assessed using an endoscope. The Munk score for epiphora was used to determine the functional outcome. The Munk score was graded from 0-4; a grade 0 indicates no epiphora, while grade 1 represents wiping less than twice a day, grade 2 indicates wiping 2-4 times/day, grade 3 wiping 5-10 times /day and grade 4 signifies wiping more than 15 times /day. Munk scores in 2<sup>nd</sup>, 3<sup>rd</sup> and 4<sup>th</sup> grade were considered failed DCR.

The data were collected and entered into SPSS version 23 for analysis. Quantitative variables, such as age, will be presented as mean  $\pm$  standard deviation, while qualitative variables, like gender, will be presented as frequency and percentage. Comparative data will be analyzed using a chi-square test, with significance indicated by a p-value < 0.05.

## RESULTS

This study included 97 eyes of 85 patients diagnosed with Dacryocystitis, divided into two groups based on the surgical approach. Group 1 consisted of 57 patients, while Group 2 included 40 patients. The mean age of participants in both groups was 39.4 $\pm$ 2.3 years. In Group 1, there were 15 men (26.3%) and 42 women (73.7%), while in Group 2, there were 13 men (22.5%) and 27 women (67.5%). Collectively, in both groups, 46(47.4%) patients presented with Dacryocystitis in the right eye, 38(39.4%) in the left eye and 13(13.4%) presented with both eyes affected. The average surgery time for Group 1 was 35 $\pm$ 3.2 minutes, whereas for Group 2, it was 21 $\pm$ 2.5 minutes. In group 1, 48(84.2%) patients had a successful surgery outcome, while 9(15.8%) were unsuccessful. While in group 2, 36(90%) patients had a successful outcome, while 4(10%) were unsuccessful. The outcomes for both groups were compared using the chi-square test, which gave a statistically significant result with a chi-square value of 4.97 and a p-value of

0.026. The outcomes were assessed both anatomically and functionally. It was evaluated anatomically based on the ostium size during the first three months. On the 3rd month follow-up, the DCR silicone tube was removed, and probing and syringing were performed on all patients. It was again performed at the six-month and one-year follow-ups. The functional outcome was assessed based on epiphora criteria throughout the follow-up period. We consider grade 0- 1 as a successful grade and grade 2-4 as an unsuccessful functional outcome (**Table I**), which shows that functional outcome was slightly lower than anatomical outcome in both surgical approaches. (**Table II**).

Upon assessing the anatomical outcome, it was found that 48(84%) of the EE-DCR patients had an open nasolacrimal duct, while 9(15.8%) had it blocked. The TC-DCR group showed 34(90%) patients with an open nasolacrimal duct, while 6(10%) had it blocked. In group 1, the ostium size was adequate in 47 (82.5%) of the patients, while 5(8.7%) had stenosis, 3 (5.2%) had granulomas and 2(3.5%) had synechiae with nasal septum.

In group 2, the ostium size was adequate in 36 (90%) of the patients, while 2(5%) had stenosis, 1(2.5%) had granulomas and 1(2.5%) had synechiae with nasal septum.

**Table I: Functional Outcome Based on Epiphora**

Follow-up	EE-DCR Successful	TC-DCR Successful	Chi-square value	p-value <0.05
4 <sup>th</sup> week	38	30	7.14	.007
12 <sup>th</sup> week	40	32	7.25	.007
24 <sup>th</sup> week	42	32	8.65	.030
48 <sup>th</sup> week	45	34	9.47	.002

Follow-up	EE-DCR Un Successful	TC-DCR Un Successful	Chi-square value	p-value <0.05
4 <sup>th</sup> week	19	10	10.44	.001
12 <sup>th</sup> week	17	8	19.56	.000
24 <sup>th</sup> week	15	8	19.7	.000
48 <sup>th</sup> week	12	6	9.0	.002

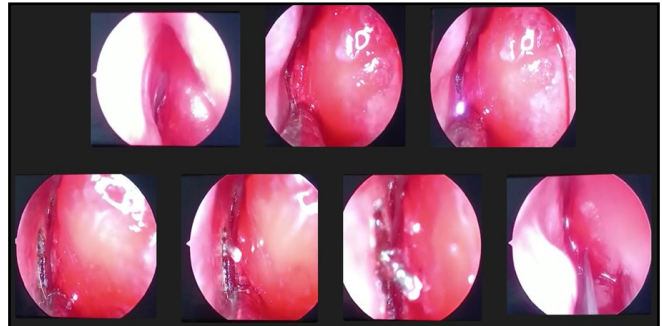
**Table II: Final anatomical and functional outcome at 12<sup>th</sup> month post-operative**

	Successful Functional Outcome	Successful Anatomical Outcome	p-value <0.05
EE – DCR	45 (78.9%)	48 (84%)	.03
TC- DCR	34 (85%)	36 (90%)	.024

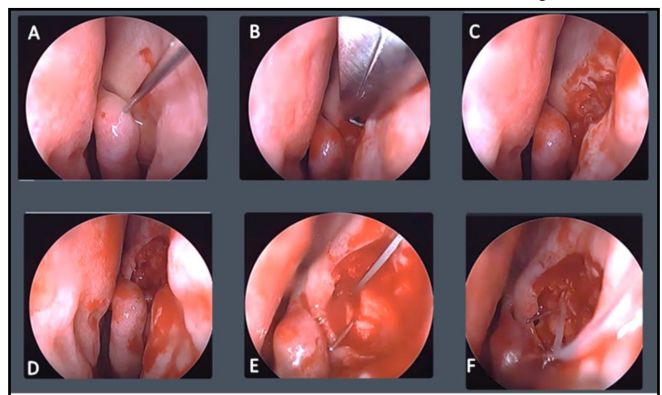
  

	Unsuccessful Functional Outcome	Unsuccessful Anatomical Outcome	p-value <0.05
EE – DCR	12 (21%)	9 (15.8%)	.04
TC- DCR	6 (15%)	4 (10%)	.001

**Picture I: Inside view of transcanalicular surgery: A. illumination of the nasal cavity with endoscope B. and C. laser beam visible. D. ostium forms E. and F. laser probe seen widening the ostium. G. silicone tube in the nasal cavity**



**Picture II: Inside view of endonasal surgery: A. Nasal cavity illuminated with an endoscope. B. Bone punch is seen creating an opening in nasal bones C and D, ostium formed E, Opening to lacrimal sac is formed with the probe in lacrimal sac F. DCR tube is seen in the nasal cavity**



**DISCUSSION**

Dacryocystitis is an acute or chronic inflammation of the lacrimal sac, often resulting from a blockage of NLD. Patients typically present with epiphora, associated with mucoid or mucopurulent discharge<sup>11</sup>. Epiphora encompasses a spectrum ranging from occasional to persistent watering, leading to mild inconvenience and socially awkward situations<sup>12</sup>. Nasolacrimal duct obstruction can be either congenital or acquired. Congenital NLD blockage is typically the result of delayed canalization of NLD and is often managed by lacrimal sac massage during 1<sup>st</sup> year of life. The acquired NLD obstruction is classified into primary and secondary. The primary NLD obstruction is characterized by inflammation and fibrosis, which develop without triggering factors<sup>13</sup>. The secondary NLD can be attributed to various factors such as infection, inflammation, neoplasm, trauma and mechanical blockage<sup>14</sup>. The prevalence of nasolacrimal duct is higher in middle-aged or older women. The smaller dimension of the lacrimal fossa and narrow mild part of NLD may increase

susceptibility to this condition in women<sup>15</sup>. The modern technological era places significant emphasis on performing surgical interventions that minimize trauma, are less invasive, and improve cosmetic outcomes with a short recovery period<sup>16</sup>. Several factors can affect the outcome of surgical procedures, including anatomical variation in the lacrimal drainage system, severity and location of obstruction. These factors play a crucial role in selecting the appropriate DCR approach<sup>17</sup>. The success rate of external DCRs is typically higher than that of internal DCRs. However, this procedure has disadvantages, such as a surgical scar mark, longer recovery time, and the possibility of nasal bleeding. Long-term side effects may include the potential for an unsuccessful DCR<sup>18</sup>. Recent advances have introduced significant changes in its treatment. Surgeons increasingly opt for the EE-DCR and TC-DCR, which are essential in managing acute and chronic Dacryocystitis<sup>19</sup>. Both of these procedures have gained popularity due to their cosmetic benefits, less invasive nature, shorter procedure times, and faster rehabilitation, all with a reduced risk of complications<sup>20</sup>. The surgeon's experience and expertise with various DCR techniques are crucial in determining the most suitable procedure<sup>21</sup>. Aslam MA 2019<sup>22</sup> conducted a study in which they found that the anatomical success rate of EE-DCR was 96.2%, with an average duration of surgery lasting 57.08 minutes. In a study by Ozturker C et al.<sup>23</sup> the outcomes of external DCR, TC-DCR and EE-DCR were compared. External DCR was more successful, with a success rate of 84.0%, compared to EE-DCR at 70.2% and TC-DCR at 65.8%. According to research by Lemaitre S 2021<sup>24</sup>, 37 patients were included in this study. Of 37 patients, 18 presented with chronic epiphora and 19 with chronic Dacryocystitis. The anatomical outcome was 78% for chronic epiphora and 76% for chronic Dacryocystitis. The functional success rate was slightly higher in chronic Dacryocystitis, 62%, than in chronic epiphora, 41%. In a study conducted by Awais M 2020<sup>25</sup>, a total of 73 participants were enrolled, consisting of 27 men and 46 women. The mean age of the participants was 51.6±21 years. The study analyzed functional and anatomical success rates of 86.3% and 93.2%, respectively. Sabaner MC et al.<sup>26</sup>, conducted a study that included 116 patients with a mean age of 49.6±11.4 years. The majority of patients were women (57.8%). The success rate for the procedure was 84.5% in the 12<sup>th</sup> month, 80.2% in the 24<sup>th</sup> month, and 76.7% in the 36<sup>th</sup> month. Takot T 2023<sup>27</sup> conducted a study comparing the EE-DCR outcome versus TC-DCR. This study included 87 patients, 14 (18.7%) men and 61 (81.3%) were women. The success was 78.5% and 84.4% in EE-DCR and TC-DCR, respectively. In this study, we analyze the surgical outcomes of EE-DCR and TC-DCR in 57 and 40 participants, respectively. All patients were assessed clinically for

functional and anatomical outcomes. The result was that TC-DCR was slightly higher, 90%, than EE-DCR, 84.2%. This research provides a significant beneficial option for the treatment plan related to Dacryocystitis. The success rate depends upon the surgeon's expertise, ostium size, and any associated abnormality of the nasal septum. Proper clinical evaluation can improve the outcome and give a better idea of the surgical approach for patient suitability. According to our study, both approaches were safe and effective; however, transcanalicular was safer and had fewer chances of complications.

## CONCLUSION

Both the EE-DCR and TC-DCR were effective for treating acute and chronic Dacryocystitis. The best outcomes can be achieved through accurate pre- and post-operative assessment and patient selection. The TC-DCR is an innovative and effective treatment compared to EE-DCR, offering several advantages, including a minimally invasive procedure, not requiring the involvement of an ENT surgeon and minimal nasal intervention. The surgeon's expertise was a critical factor in the procedure's success.

## ACKNOWLEDGEMENT

We thank Ayesha Khalid and Maryam Shifa for the statistical analysis and patient counseling.

**Ethical permission:** Ziauddin University Hospital, Karachi, ERC letter No. ZHK/HR/7342807/ 2021.

**Conflict of Interest:** No conflicts of interest.

**Financial Disclosure / Grant Approval:** No funding agency was involved in this research.

**Data Sharing Statement:** The corresponding author can provide the data proving the findings of this study on request. Privacy or ethical restrictions bound us from sharing the data publicly.

## AUTHOR CONTRIBUTION

Khalid A: Concept, design, and leading contributor in writing the manuscript Interpretation of data. Performed surgeries

Sultan S: Edited and contributed in writing the manuscript Interpretation of data

Khanzada MA: Edited and contributed in writing the manuscript Interpretation of data

Wasif M: Performed surgeries patient selection and proofread the article

Bhatty A: Patient selection, references, and proofreading of the article.

Fatima A: Literature research for discussion and references

## REFERENCES

1. Nowak R, Rekas M, Gospodarowicz IN, Ali MJ. Long-term outcomes of primary transcanalicular laser dacryocystorhinostomy. *Graefes Arch Clin Exp Ophthalmol.* 2021; 259(8): 2425-30. doi: 10.1007/s00417-021-05165-5. Epub 2021 Mar 26.
2. Pinto C, Queirós T, Ferreira C. Transcanalicular

- diode laser-assisted dacryocystorhinostomy - success rates and related factors during 3 years of follow-up. *Semin Ophthalmol.* 2021; 36(7): 501-6. doi: 10.1080/08820538.2021.1890785. Epub 2021 Mar 18.
3. Yener HI, Ozcimen M. Long-term results in transcanalicular laser and external dacryocystorhinostomy. *Beyoglu Eye J.* 2020; 5(1): 22-5. doi: 10.14744/bej.2019.80299.
  4. Bulut A, Aslan MG, Oner V. Transcanalicular Multidiode Laser Versus External Dacryocystorhinostomy in the Treatment of Acquired Nasolacrimal Duct Obstruction. *Beyoglu Eye J.* 2021; 6(4): 315-319. doi: 10.14744/bej.2021.04934.
  5. Akcam HT, Konuk O. Mechanical transnasal endoscopic dacryocystorhinostomy versus transcanalicular multidiode laser dacryocystorhinostomy: long-term results of a prospective study. *Lasers Med Sci.* 2020; 36(2): 349-56. doi: 10.1007/s10103-020-03038-7. Epub 2020 May 20.
  6. Mutlu D, Bayram N, Arici MK, Ozec AV, Erdogan H, Toker MI. Comparison of Outcomes of External Dacryocystorhinostomy and Transcanalicular Laser-Assisted Dacryocystorhinostomy in Patients with Primary Acquired Nasolacrimal Duct Obstruction. *Klin Monbl Augenheilkd.* 2022; 239(6): 799-803. doi: 10.1055/a-1720-1752. Epub 2022 Feb 18.
  7. Jasim AD, AhmedAAQ, Khaleel MA. Transcanalicular laser dacryocystorhinostomy as a recent approach for treating nasolacrimal duct obstruction at Al-Mosul teaching centre. *Int J Surg Sci* 2019; 3(3): 313-317. doi: 10.33545/surgery.2019.v3.i3f.187.
  8. Herzallah I, Marglani O, Alherabi A, Faraj N, Bukhari D. Bilateral simultaneous endoscopic dacryocystorhinostomy: outcome and impact on the quality of life of the patients. *Int Arch Otorhinolaryngol.* 2019; 23(2): 191-5. doi: 10.1055/s-0038-1675394.
  9. Goel R, Sagar C, Gupta SN, Shah S, Agarwal A, Golhait P et al. Outcome of transcanalicular laser dacryocystorhinostomy with endonasal augmentation in acute versus post-acute Dacryocystitis. *Eye (Lond).* 2023; 37(6): 1225-230. doi: 10.1038/s41433-022-02104-4. Epub 2022 May 19.
  10. Chong KK, Abdulla HAA, Ali MJ. An update on endoscopic mechanical and powered dacryocystorhinostomy in acute Dacryocystitis and lacrimal abscess. *Ann Anat.* 2020 Jan;227:151408.
  11. Yu B, Qian Z, Han X, Tu Y, Wu W. Endoscopic Endonasal Dacryocystorhinostomy With a Novel Lacrimal Ostium Stent in Chronic Dacryocystitis Cases With Small Lacrimal Sac. *J Craniofac Surg.* 2020; 31(5): 1348-1352. doi: 10.1097/SCS.0000000000006359.
  12. Evereklioglu C, Horozoglu F, Polat OA, Sonmez HK, Sener H, Arda H. Modified external revision-DCR in previous failed endonasal, transcanalicular or external-DCR: technical strategy and teaching Pearls for success. *Rom J Ophthalmol.* 2023; 67(1): 14-19. doi: 10.22336/rjo.2023.4.
  13. Tariq M, Jamil AZ, Ali S, Khalid M, Akash A. Comparison of Endonasal Endoscopic Dacryocystorhinostomy with External Dacryocystorhinostomy. *Pak J Ophthalmol.* 2021; 37(3): 317-321. doi: 10.36351/pjo.v37i3.1226.
  14. Hamal D, Kafle PA, Lamichhane B, Anwar A, Singh SK. Endoscopic Endonasal Dacryocystorhinostomy under Local Anesthesia or Assisted Local Anesthesia. *Nepal J Ophthalmol.* 2022; 14(27): 10-18. doi: 10.3126/nepjoph.v14i1.21971.
  15. Jwad AA, Albusalih WA. Endoscopic Endonasal Dacryocystorhinostomy Vs LASER-Assisted Dacryocystorhinostomy: Comparative Study. *Ann Roman Soc Cell Biol.* 2021; 25(4): 1545-50.
  16. Havuz E, Albayrak S, Gurkaynak MN. Endoscopic Endonasal Dacryocystorhinostomy in Persistent Congenital Nasolacrimal Duct Obstructions. *Acta Scientif Ophthalmol.* 2020; 3(3): 45-51. doi: 10.31080/ASOP.2020.03.0103.
  17. Maldhure SV, Golhar PS, Moon PP. Endonasal Dacryocystorhinostomy: Results with or Without Stenting. *Cureus.* 2023; 15(1): e33470. doi: 10.7759/cureus.33470.
  18. Tripti, Havle AD, Vihapure GM, Shedge SA. Etiological Factors of Failure in Endonasal Dacryocystorhinostomy. *Indian J Public Health Res Develop.* 2020; 11(3): 917-920. doi: 10.37506/ijphrd.v11i3.1487.
  19. Kumar S, Mishra AK, Sethi A, Mallick A, Maggon N, Sharma H et al. Comparing outcomes of the standard technique of endoscopic DCR with its modifications: A retrospective analysis. *Otolaryngol Head Neck Surg.* 2019; 160(2): 347-54. doi: 10.1177/0194599818813123.
  20. Lunardi G, Schiavo P, Amadori R, Cellina M, Termine G. The Endoscopic Endonasal Dacryocystorhinostomy (eDCR) in the Immunocompromised Patient. *Indian J Otolaryngol Head Neck Surg.* 2023; 75(Suppl 1): 962-5. doi: 10.1007/s12070-023-03515-9.
  21. Shahid M, Awais M, Akram A, Naqvi SAH, Zafar O, Malik TM. Endoscopic Endonasal Dacryocystorhinostomy: Experience of Hundred Cases. *Pak Armed Forces Med J.* 2021; 71(6): 2104-2108.
  22. Aslam MA, Shahzad J. Is endonasal endoscopic Dacryocystorhinostomy is a safe and successful procedure: An audit of 106 cases. *ISRA Med J.* 2019; 11(5): 376-379.
  23. Ozturker C, Purevdorj B, Karabulut GO, Seif G, Fazil K, Khan YA et al. A Comparison of Transcanalicular, Endonasal, and External

- Dacryocystorhinostomy in Functional Epiphora: A Minimum Two-Year Follow-Up Study. *J Ophthalmol.* 2022; 2022: 3996854. doi: 10.1155/2022/3996854.
24. Lemaitre S, Sarandeses-Diez T, Gonzalez-Candial M. Anatomical and functional outcomes of transcanalicular diode laser assisted dacryocystorhinostomy as a primary procedure. *J Fr Ophtalmol.* 2021; 44(3): 404-408. doi: 10.1016/j.jfo.2020.05.028. Epub 2021 Jan 22.
25. Awais M, Naqvi SAH, Akram A, Shahid M. Transcanalicular diode laser assisted dacryocystorhinostomy: A breakthrough in the treatment of acquired nasolacrimal duct obstruction. *Pak J Med Sci.* 2020; 36(4): 804-807. doi: 10.12669/pjms.36.4.1906.
26. Sabaner MC, Kahveci OK, Duman R, Erol MA, Çetinkaya E, Yigit K et al. The long-term outcomes of transcanalicular diode laser-assisted endoscopic dacryocystorhinostomy in isolated nasolacrimal duct obstruction. *Gulhane Med J.* 2021; 63: 170-4. doi: 10.4274/gulhane.galenos.2020.1300.
27. Tokat T, Tokat S, Kusbeci T. Long-Term Outcomes of Transcanalicular Laser Dacryocystorhinostomy Versus Endonasal Dacryocystorhinostomy and a Review of the Literature. *Niger J Clin Pract.* 2023; 26(8): 1069-1074. doi: 10.4103/njcp.njcp\_349\_22.

