

# A Full Mouth Rehabilitation of a Patient with Calcific Metamorphosis

Zaid Al Jeaidi, Shahid Mahmood

## ABSTRACT

Calcific metamorphosis (CM) is a condition which can be observed after trauma to teeth, due to deposition of hard tissues within the root canal space. It results in complete obliteration of the root canal space and yellow discoloration of the teeth. There is a difference of opinion on the management of CM, from no intervention to immediate intervention. This case report describes the diagnosis and management of a patient with CM. In addition to CM, the patient suffered from generalized plaque induced gingivitis, multiple carious lesions, necrosis of teeth, external root resorption and some missing teeth. The patient was a 34-year-old, male, Saudi patient, who was provided with oral prophylaxis, simple restorations, endodontic treatments, an on lay and a ceramic crown, restoration of the anterior dentition with porcelain laminate veneers, and finally the dental implants to replace missing teeth. Thus, this report describes not only the diagnosis and management of CM, but also how to design and implement a comprehensive treatment plan for the welfare of a patient.

**KEYWORDS:** Calcific metamorphosis, porcelain laminate veneers, dental implants.

*This article may be cited as:* Al Jeaidi Z, Mahmood S. A Full Mouth Rehabilitation of a Patient with Calcific Metamorphosis. J Liaquat Uni Med Health Sci. 2020;19(01):69-72.  
doi: 10.22442/jlumhs.201910665

## INTRODUCTION

Calcific metamorphosis (CM) is a feature that can be observed after trauma to dental tissues, resulting in deposition of hard tissues in the root canal space and yellow discoloration of teeth<sup>1</sup>. The management of the patients with CM varies from immediate root canal treatments (RCT) to wait till the appearance of symptoms or evidence of necrosis radiographically<sup>1</sup>. Approximately 3.8% to 24% of traumatized teeth have been reported to develop CM, with 1-16% progressing to pulpal necrosis<sup>1</sup>. As trauma usually involves the anterior teeth, yellow discoloration resulting from CM may be a major concern of the patients.

It is essential that when a patient presents to a dental clinic, a comprehensive treatment plan is devised to address all problems as a whole<sup>2</sup>. Where indicated, the techniques, such as, porcelain laminate veneers (PLVs and Implant-supported prostheses (ISP) and provide an increased patient satisfaction due to better esthetics, and function<sup>3</sup>. The long-term success of treatments, however, still depends on the success of the measures taken for prevention for future disease process, in line with the philosophy of minimal intervention dentistry<sup>4</sup>.

This paper aims to present a clinical case of full-mouth rehabilitation of a patient with CM, generalized plaque induced gingivitis, carious lesions, external root resorption, necrosis of teeth, and some missing teeth.

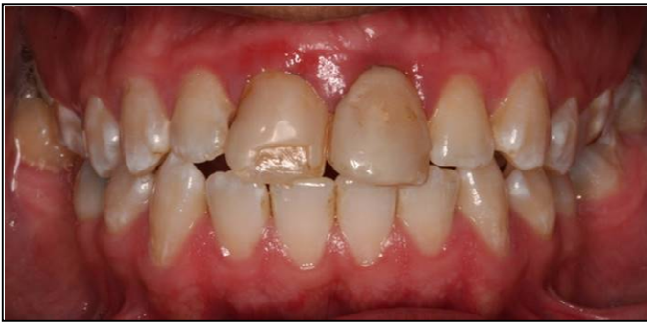## CASE REPORT

A 34-year-old male patient, male, a teacher by profession, with no history of medical diseases, reported with a desire to improve the appearance of his front teeth and to replace his missing teeth **Figure I**. The patient had a trauma during childhood to his anterior teeth, at the age of 12 years, resulting in yellow discoloration of tooth # 11 **Figure I**. Tooth #11, showed root canal obliteration on periapical radiograph and thus could be diagnosed as with calcific metamorphosis **Figure II**. Tooth # 21, 15, and 37 were necrosed. An external resorption with grayish discoloration was observed in tooth # 21 as well **Figure III**.

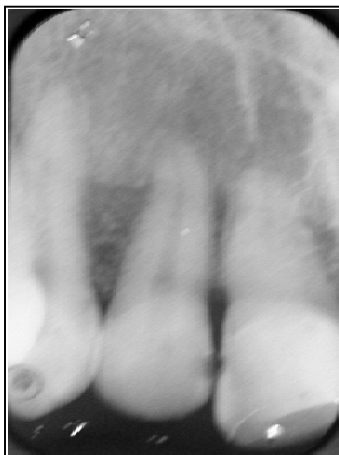The oral hygiene of the patient was poor and showed his neglect. The examination demonstrated generalized blunt interdental papilla, with swollen rolled edematous margins and bleeding upon probing, indicative of generalized plaque induced gingivitis. The tooth # 17, 16, 15, 14, 11, 24, 25, 26, 27, 37, 44, 45 & 48 were carious. Tooth # 36 and 46 and 47 were missing **Figure IV**.

Smile analysis showed that the midline of the mandibular teeth was not in line with the midline of the opposing maxillary teeth. About 4 mm of maxillary central incisor teeth structure showed, when the lips were at rest. In terms of the Occlusion, patient had a Class I Canine to Canine relationship. Horizontal and vertical overlap was 1mm **Figure V**.

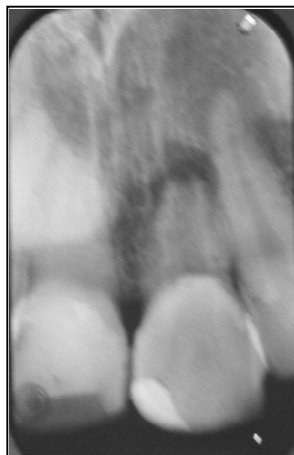
**Figure I: Pre-Operative image of the patient showing discoloration of tooth #11 (Calcific Metamorphosis) and missing teeth**



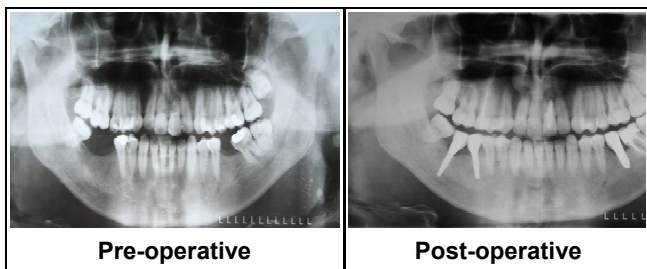
**Figure II: Pre-Operative Radiograph showing obliterated root canal space in tooth # 11 (Calcific Metamorphosis)**



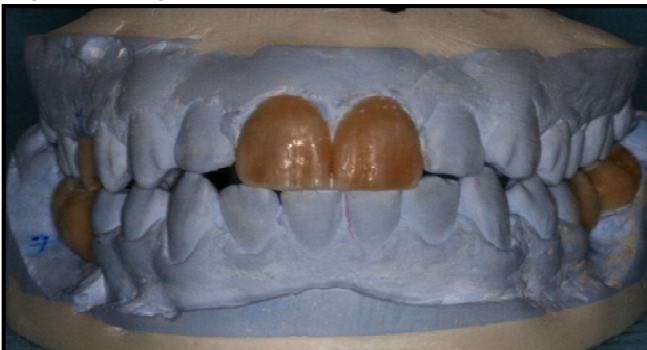
**Figure III: A radiograph showing external root resorption in tooth # 21**



**Figure IV: Pre-Operative and post-operative Orthopentograms**



**Figure V: Diagnostic wax-up**



### INVESTIGATIONS

An orthopentogram (OPG) radiograph and full mouth survey of intraoral periapical radiographs was undertaken **Figure III**. Diagnostic casts were mounted and diagnostic wax up was done to design the anterior PLVs and ceramic crown **Figure V**. Electric pulp test and cold test with ice revealed no response on tooth # 21, 15 and 37.

### TREATMENT

A phase-wise treatment plan was prepared and approved with the consent of the patient. The phases of treatment were: Prophylaxis phase, restorative phase, endodontic phase, surgical phase and prosthodontic phase, in order.

The treatment was initiated with Oral prophylaxis with ultrasonic scalers and the patient was advised on oral hygiene methods. Fluoride gel was applied weekly to reduce chances of future caries. The tooth #17, 16, 15, 14, 24, 25, 26, 27, 37 & 44 were restored with resin composite and 48 with amalgam. Tooth # 15, 21 and 37 were treated with a RCT, followed by pre-fabricated Post and composite cores. Tooth # 45 was restored with a porcelain On lay **Figure VI**.

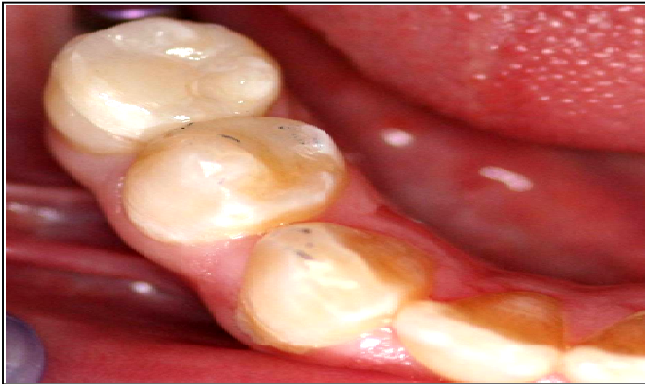The tooth # 11, with CM was restored with PLV without RCT and was kept under observation. PLV were provided for tooth # 12 and 11 for esthetic reasons (Fig. 7). Tooth # 21, showing radiographic external resorption **Figure III**, was treated with Mineral Trioxide (MTA) and restored with a ceramic crown. For preparation of PLVs (IPS Empress, Prostetiki Dental Laboratory, Austria) a sub-gingival chamfer finish line was used with the preparation extending lingually beyond the incisal edge. This feature helps in the proper seating of the final veneer **Figure VII**.

Missing teeth, # 36, 45 & 46 were replaced with Implants-supported prostheses **Figure VIII**. Implants (Nobel Biocare, Switzerland) were placed using the "two stage technique". Cone beam computerized tomography (CBCT) scan showed adequate height and width of bone at all implant sites. In tooth # 36, a drill hole was made 13 mm deep and 3.5 mm wide. The implant was placed of the dimension of 3.5 mm x 10 mm taking extreme care because of a low-density bone. Bone grafting was done and the flap was sutured. Subsequently, two implants were placed in tooth # 46 (3.5 x 13 mm) and 47 (3.5 x 13 mm). After ten weeks, the second stage surgery was performed. a small crestal incision was given exposing the implants, and healing abutments were placed. After the implant placement and second-stage surgery, interim restorations were placed.

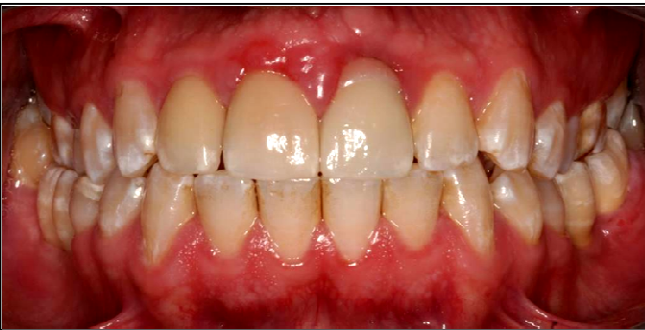The final prostheses were delivered and the prostheses screws were tightened to the force of 25 N/cm<sup>2</sup>. The three-year follow-up at six monthly intervals showed complete healing and full satisfaction

of the patient in terms of esthetics and function  
**Figure IX.**

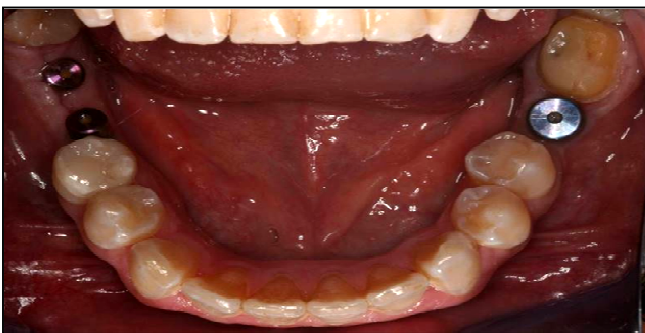**Figure VI: Porcelain On lay on tooth # 45**



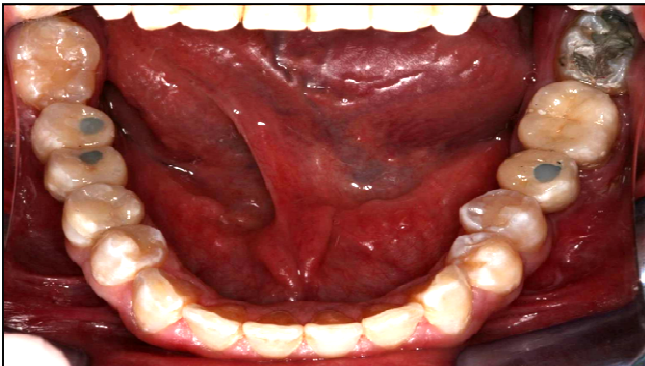
**Figure VII:**  
An image showing the completed treatment including  
Porcelain laminate veneers in tooth # 11 and 21



**Figure VIII:**  
A photograph showing placement of three implants



**Figure IX: Implant supported prostheses inserted**



## DISCUSSION

Calcific metamorphosis, a complication of dental trauma, has been reported in 3.8% to 24% of cases, with 1% to 16% reported cases of root canal obliteration<sup>1</sup>. In cases of obliteration, because of the probability of procedural errors in performing conventional RCT, it is recommended to observe and follow-up in the absence of symptoms or a periapical pathosis<sup>5</sup>. As in this case, where the patient's complaint was only discoloration, bleaching or PLVs are recommended for esthetic reasons, without conventional RCT<sup>5</sup>. A PLV was provided on tooth #11 with CM, and excellent esthetic results were achieved without bleaching as the discoloration was only limited. PLVs used in this case contained Fluorapatite glass-ceramics, thus providing thinner veneers, and yet enough strength<sup>6</sup>.

External root resorption, as was evident in tooth #21, is a lytic process occurring in the cementum and dentin of the roots. Mineral trioxide (MTA) because of its alkalinity and sustained calcium hydroxide release has been recommended for its management, as was done in this case<sup>7</sup>.

For replacement of missing teeth, current research recommends one implant for each missing tooth. Therefore, in the present case, three implants were placed for the three missing teeth. The critical performance of the screw joint is affected by the handling of the screw seat. Discrepancy between the screw seat and the retentive screw may lead to early screw loosening. Although immediate loading is admired by the patients, the chances of failure are enhanced in cases of immediate loading.<sup>8</sup>Therefore, a "two stage" surgical technique is preferable.

Cement retained implant restorations are simple, esthetic and more economical. However, such restorations are difficult to be retrieved, and any residual cement in the soft tissues surrounding the implant may lead to peri-implant disease. A screw retained prostheses design was selected to allow easy retrievability and maintenance, and therefore a better success<sup>9</sup>.

In terms of oral hygiene status, a significant improvement was not observed, which could be related to the poor compliance of the patient, as indicated in the introduction of this case report. A lack of compliance, though essential for the success of a treatment has been reported elsewhere as well<sup>10</sup>. A thorough follow-up and monitoring is essential for the success of any treatment admittedly.

## CONCLUSION

Excellent results can be achieved, in cases of conditions like Calcific Metamorphosis and those requiring full-mouth rehabilitation by a treatment

based on prevention, and application of the latest techniques.

## REFERENCES

1. Amir FA, Gutmann JL, Witherspoon DE. Calcific metamorphosis: a challenge in endodontic diagnosis and treatment. *Quintessence Int.* 2001; 32(6): 447-55.
2. Saeidi PR, Freitas RC, Engler MLPD, Edelhoff D, Klaus G, Prandtner O, et al. Historical development of root analogue implants: a review of published papers. *Br J Oral Maxillofac Surg.* 2019; 57(6): 496-504.
3. Durkan R, Oyar P, Deste G. Maxillary and mandibular all-on-four implant designs: A review. *Niger J Clin Pract.* 2019; 22(8): 1033-1040.
4. Allen PF, Da Mata C, Hayes M. Minimal intervention dentistry for partially dentate older adults. *Gerodontology.* 2019; 36(2): 92-98. doi: 10.1111/ger.12389.
5. McCabe PS, Dummer PM. Pulp canal obliteration: an endodontic diagnosis and treatment challenge. *Int Endod J.* 2011; 45(2): 177-97. doi: 10.1111/j.1365-2591.2011.01963.x.
6. Nejatidanesh F, Savabi G, Amjadi M, Abbasi M, Savabi O. Five year clinical outcomes and survival of chairside CAD/CAM ceramic laminate veneers - a retrospective study. *J Prosthodont Res.* 2018; 62(4): 462-7. doi:10.1016/j.jpor.2018.05.004.
7. Ashwini TS, Hosmani N, Patil CR, Yalgi VS. Role of mineral trioxide aggregate in management of external root resorption. *J Conserv Dent.* 2013; 16(6): 579-81. doi: 10.4103/0972-0707.120937.
8. Tallarico M, Vaccarella A, Marzi GC. Clinical and radiological outcomes of 1- versus 2-stage implant placement: 1-year results of a randomised clinical trial. *Eur J Oral Implantol.* 2011; 4(1): 13-20.
9. Makke A, Homsy A, Guzaiz M, Almalki A. Survey of Screw-Retained versus Cement-Retained Implant Restorations in Saudi Arabia. *Int J Dent.* 2017; *Int J Dent.* 2017; 5478371. doi: 10.1155/2017/5478371.
10. Smith AJ, Moretti AJ, Brame J, Wilder RS. Knowledge, attitudes and behaviours of patients regarding interdental deplaquing devices: A mixed methods study. *Int J Dent Hyg.* 2019; 17(4): 369-80. doi: 10.1111/idh.12410.



*AUTHOR AFFILIATION:*

**Dr. Zaid Al Jeaidi**

Associate Professor  
Department of Conservative Dental Sciences  
Prince Sattam Bin Abdul Aziz University  
Alkharj, Saudi Arabia.

**Dr. Shahid Mahmood** (*Corresponding Author*)

Professor, Department of Conservative Dental Sciences  
Prince Sattam Bin Abdul Aziz University,  
Alkharj, Saudi Arabia.  
Email: s.akram@psau.edu.sa