

# Ponseti Technique in Neglected Club Foot Children with Age between 3 and 11 Years

Muhammad Jamil, Adeel Ahmed Siddiqui, Kashif Mahmood Khan, Jagdesh Kumar, Muhammad Soughat Katto, Malik Wasim Ahmed, Mehtab Ahmed Pirwani

## ABSTRACT

**OBJECTIVE:** To evaluate the Ponseti treatment in neglected club foot patients. Result of this study shall help us to manage untreated or neglected patients with club foot in better way and this study shall provide platform for bigger studies on clubfoot in Pakistan.

**METHODOLOGY:** This multicentre observational cross sectional study was conducted on retrospective data of patients registered to Ponseti Club foot Clinic between July 2013 to Dec 2016 at Dr Ruth Pfau Civil Hospital Karachi and Jinnah postgraduate Medical Center, Karachi. In this study 41 feet in 28 patients with Neglected club foot between 3 to 11 years were treated by Ponseti guidelines for older child (already walking child). Deformity was assessed with pirani scoring. Average follow up time was 3 years.

**RESULTS:** Painless plantigrade foot was obtained in all patients. In 3 patients equinus deformity recurred. Two were managed with recasting while in the third one along with recasting and retenotomy was undertaken. In 2 patients mild varus was recurred, which was managed with recasting. One patient was lost to follow-up after 2 years.

**CONCLUSION:** This study conclude that treatment of neglected idiopathic club foot patients presenting to us after walking age with Ponseti method according to Ponseti guidelines for older children is safe, effective and low cost method. It also reduces the risk of excessive surgical procedures.

**KEYWORDS:** Ponseti technique, Neglected Club foot, Club foot.

*This article may be cited as:* Jamil M, Siddiqui AA, Khan KM, Kumar J, Katto MS, Ahmed MW, et al. Ponseti Technique in Neglected Club Foot Children with Age between 3 and 11 Years. J Liaquat Uni Med Health Sci. 2019;18(01):17-21. doi: 10.22442/jlumhs.191810595

## INTRODUCTION

Club foot or Congenital Talipes Equinovarus (CTEV) is a complex foot deformity which consists of adducted forefoot, cavus midfoot and equinovarus hindfoot<sup>1,2,3</sup>, which is usually bilateral and is more common in male newborns<sup>1</sup>. It is most common congenital foot deformity and this condition affects 1 and 7 births in every 1000 individuals worldwide<sup>4</sup>. In Pakistan, where 5.3 million births occur every year the prevalence of club foot would be 6000–7000 every year i.e. 1.4:1000 live births<sup>1</sup>.

Orthopaedists believe that initially its treatment should be non-operative<sup>1</sup>. The first pioneer who has introduced non-operative treatment was Kite<sup>1</sup>, but this method takes longer time for correction and successful results were only in patients treated by Kite<sup>5</sup>. which was modified in early 1940's by Dr Ignacio Ponseti<sup>1</sup>. Ponseti Method has become very popular and vastly achieved improved results, the basic aim was to correct all components of deformity in order to achieve painless, plantigrade foot with good mobility without the need of special shoes<sup>1</sup>. A simple percutaneous tendo achilles tenotomy often is necessary to correct completely the equinus<sup>1</sup>.

This method has been proved successful in many institutions up to the age of 9 years<sup>6</sup>. Morcuende JA 2004<sup>1</sup> has considered Ponseti method, as a first line treatment, reducing the number of extensive corrective surgery and relapses<sup>1</sup>, he believed that manipulation of the foot should start as soon as possible<sup>7</sup>. A study was successful in treating 9 out of 11 patients with a mean age of 11.2 (range between 6 -19 years) with neglected and untreated club foot by some modifications in the Ponseti method<sup>8</sup>. Another successful prospective study was done on 41 feet of 30 patients with mean age of 3.02 (range 1-10.3 years)<sup>9</sup>. Khan SA 2010<sup>10</sup> has concluded that Ponseti treatment should be the initial treatment even in the neglected cases. Neglected club foot is defined as the club foot not treated up to walking age<sup>4</sup>. The neglected cases are more common in poor people living in areas with less medical facilities needed for the treatment of club foot<sup>11</sup>, also it has been noticed that repeated soft tissue release leads to long term functional disability; joints get stiff and there are chances of getting arthritis of foot early in age<sup>12</sup>. Despite clubfoot being prevalent in Pakistan, we do not have ample data available on techniques, outcomes and complications of management for Pakistani pediatric population.

Considering the paucity of data, our primary objective of this study is to evaluate the Ponseti treatment in older children who are either untreated or neglected. Result of this study shall help us to manage untreated or neglected patients with club foot in better way and this study shall provide platform for bigger studies on clubfoot in Pakistan.

**METHODOLOGY**

This retrospective multicentre observational cross sectional study with Non probability consecutive sampling technique was conducted on retrospective data from patients registered to ponseti clinic during July 2013 to Dec 2016 in the department of Orthopaedics at Dr Ruth K.M Pfau Civil Hospital Karachi and Jinnah Post Graduate Medical Centre (JPMC) in Karachi. This study evaluated retrospectively via club foot registry of 41 feet in 28 consecutive children of neglected idiopathic club feet between 3 to 11 years of age who were treated by Ponseti guidelines for older child (already walking child). We excluded all other types of club feet. Other types includes syndromic club foot, treated club foot, and club foot beyond the age of our inclusion criteria.

The required information was gathered through a review of medical record for patient's demographic data, Pirani Score, number of cast, Surgical procedure (Achillies tendon percutaneous tenotomy and / or lengthening + posterior capsulectomy),pre and post cast documented photographs and complications related to procedure on a structured proforma designed for this study.

Pirani scoring was used retrospectively to evaluate results. Pirani scoring is easy, widely used and predictable about the likely treatment of the club foot<sup>13</sup>. The Pirani scoring system consists of 6 categories, 3 each in the hind foot and the midfoot. They were between 4 or 5 Pirani score. There was no empty heel sign in all patients. No previous treatment was done for these patients.

In all children treatment was done according to Ponseti guidelines for older child (already walking child). Manipulations were performed by the primary author that lasted for approximately 5 minutes. Then Long leg cast was applied that were changed weekly for the first 3 cast and the rest were changed every 2 weeks. After getting 30 to 40 degrees of abduction, Equinus was corrected by percutaneous tenotomy of Achillestendon under local anesthesia up to 7 years of age. In children older than 7 years, Achillestendon lengthening was done along with posterior capsulotomy under general anesthesia by the author. Long leg cast was applied for 4 weeks for patients upto age 7 years and it was used for 6 weeks in greater than 7 years age.

After getting 30 to 40 degrees of abduction and 10 to

20 degrees of dorsiflexion, a standard foot abduction brace was given. Brace was used 16 to 18 hours a day up to 3 months for the club foot patients of 7 years of age and after that during night time for 2 years. In club foot patients > 7 years of age night time foot abduction brace were applied for 2 years. All feet in this study were followed for an average period of 3 years and were evaluated by using a Pirani scoring.

SPSS Version 20.0 was used to analyze data. Mean was calculated for age and number of casts. Frequency was used to calculated degrees, recurrences and complications.

**RESULTS**

Of 28 patients 17 were male and 11 were females with age between 3 and 11 years mean age 5.24 years ± 2 described in Table I. All patients had severe deformity with mean 5 Pirani score. Except equinus deformity, all deformities were corrected by serial casting. Correction was obtained with a mean of 09 casts (6 to 14). The no of cast increases with age and severity of Pirani score. Midfoot was corrected to pirani score 0 with casts in all patients. Equinus corrected with percutaneous tendonotomy or tendon Achilles lengthening, along with posterior capsulotomy depending on age of the patient.

In patients up to 7 years abduction up to 40 to 50 degrees was achieved, while in older abduction of 30 to 40 degrees was achieved. Dorsiflexion of 10 to 20 degrees achieved in patient age up to 7 years while in older 10 to 15 degrees of dorsiflexion achieved. There were mild complications with casting. 3 patients had swelling of toes, 5 had redness of skin due to excessive pressure that were managed without any treatment. No major complications were observed with minor surgical procedures.

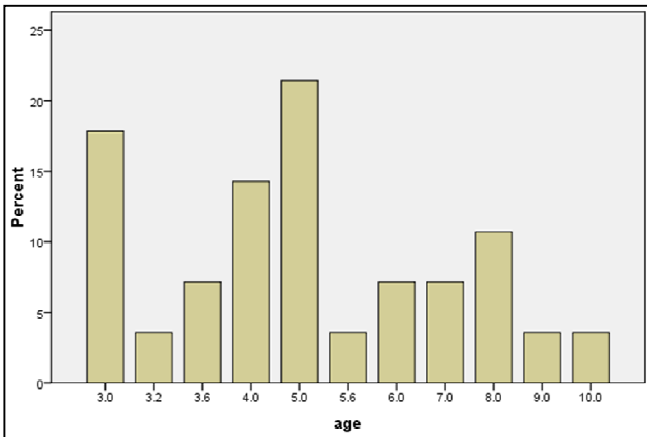
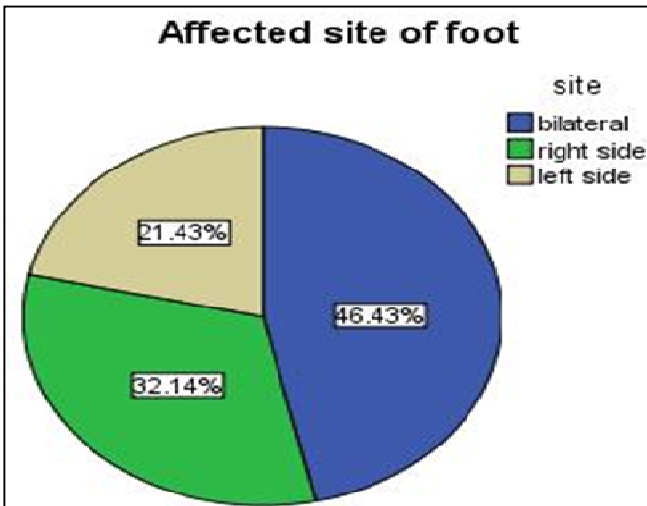
In 3 patients, equines deformity was recurred, of them two were managed with recasting while in third one along with recasting retentomy was undertaken. In 2 patients mild varus deformity was recurred that was managed with recasting. One patient lost follow-up after 2 years. Results described in Table II.

**TABLE I: DEMOGRAPHICS**

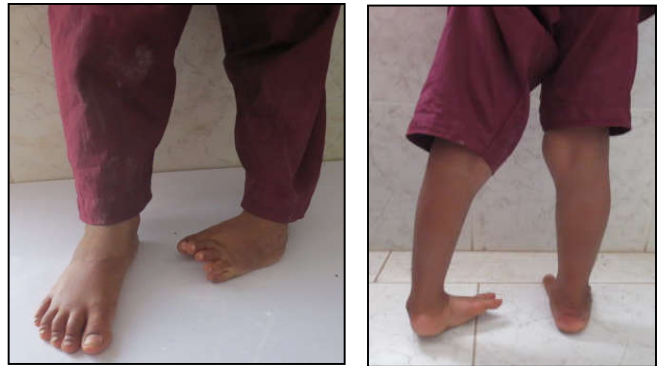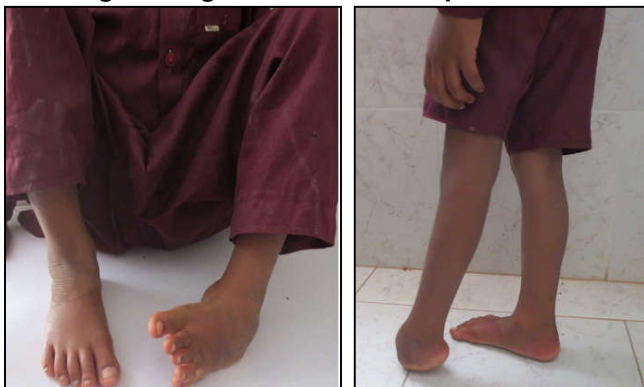Age	N (%)
Mean (years)	5.24 ± 2.00
<b>Gender</b>	
Male	17 (60.7%)
Female	11 (39.3%)
<b>Site of Club foot</b>	
Right	9 (32.1%)
Left	6 (21.4%)
Bilateral	13 (46.4%)
<b>Total number of feet</b>	
Riht+left+bilateral	41(100%)

**TABLE II: RESULTS**

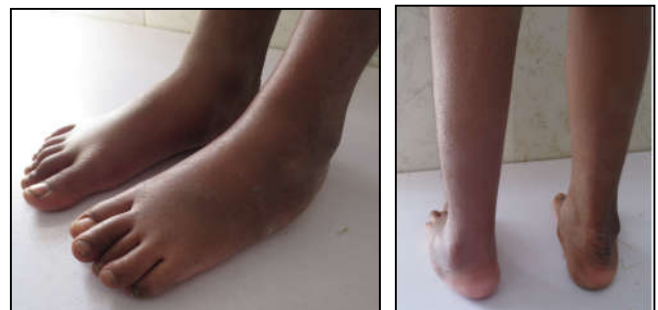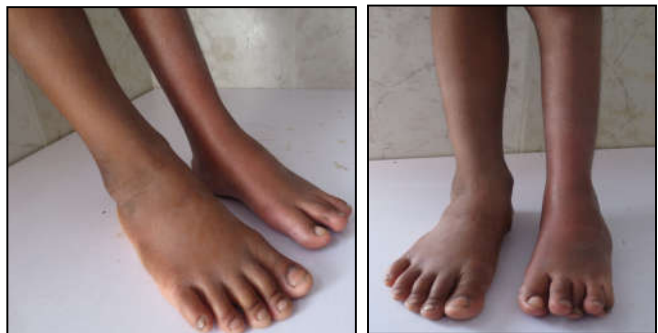		Frequency	Percent
Valid	No relapse	22	78.6
	Treated with relapse	5	17.9
	Lost follow-up	1	3.6
	Total	28	100.0



**Clinical photographs of an eight-year-old boy showing left neglected clubfoot at presentation**



**Clinical Photographs of an eight-year old boy showing left neglected clubfoot 2 years after treatment of manipulation and serial casting for 3 months (Nine casts and Tendo Achilles lengthening)**



**DISCUSSIONS**

In our study correction was obtained with mean of 9 casts. In patients up to 7 years abduction up to 40 to 60 degrees achieved, while in older abduction of 30 to 40 degrees achieved. Dorsiflexion of 10 to 20 degrees achieved in patient age up to 7 years while in older 10 to 15 degrees of dorsiflexion achieved.

Strength of this study lies in its novelty. This is the first of its kind study in Pakistan to best of our knowledge. However the study has small sample and was conducted only in this hospital.

In our study the mean Pirani score was 5 before treatment and 0 after treatment. This is consistent with result of study by Methani<sup>14</sup>. Methani in his study had mean Pirani score of 4.3 before treatment and 0.03

after treatment<sup>14</sup>. Another study published in Indian Journal of orthopedics mean Pirani score was 5.41 before treatment and 0.12 after treatment<sup>9</sup>.

In our study, correction was obtained with a mean cast of 9. This was similar to finding of Basihi RH 2016<sup>6</sup> In his study correction was obtained with a mean cast of 9 (6 to 13). Sinha A 2016<sup>9</sup> in his study took mean 12.8 numbers of casts for correction. However in studies by Ayana B 2014<sup>15</sup>, the mean no of casts were 8.

In our study, in patients up to 5 years abduction up to 40 to 60 degrees correction was achieved, while in older abduction of 30 to 40 degrees achieved. Dorsiflexion of 10 to 20 degrees achieved in patient age up to 7 years while in older 10 to 15 degrees of dorsiflexion achieved. This is consistent with the mean dorsiflexion achieved by Sinha A 2016<sup>9</sup> in his study was 21.3 degree (15-40).

Ponseti is generally considered excellent for club foot. However if patient is not compliant with the brace treatment, recurrence of deformity may occur<sup>16</sup>. In our study 3 patients with equinus deformity had recurrence. Two were managed with recasting while in one managed with recasting and retenotomy. Two patients recur with mild varus, they were managed with recasting.

In a developing country like Pakistan, Ponseti technique is a very safe, easy, have efficacy and very economical for management of clubfoot. Proper motivation and educating the parents to get use to long-term brace treatment will not only help maintain the correction for longer period of time but also prevents relapse.

## CONCLUSION

We concluded that treatment of neglected idiopathic club foot patients presenting to us after walking age with ponseti method according to ponseti guidelines for older children is safe, effective and low cost method. Through this treatment we can achieve functional painless foot.

## RECOMMENDATION

This treatment should be considered as first modality in the management of neglected idiopathic club foot children presented after walking age.

## LIMITATION

The main limitation of this study was its retrospective design, small number of patients and lack of comparison with surgical methods, other than that we are feeling this study will help the orthopaedic surgeons who are managing neglected club foot.

## REFERENCES

1. Morcuende JA, Dolan LA, Dietz FR, Ponseti IV.

- Radical reduction in the rate of extensive corrective surgery for clubfoot using the Ponseti method. *Pediatrics*. 2004; 113(2): 376–80.
2. Kumar R, Suman SK, Manjhi LB. Evaluation of outcome of treatment of idiopathic clubfoot by ponseti technique of manipulation and serial plaster casting. *Int J Ortho Sci*. 2017; 3(4): 23-7. doi: 10.22271/ortho.2017.v3.i4a.05
3. Marquez E, Pacey V, Chivers A, Gibbons P, Gray K. The Ponseti technique and improved ankle dorsiflexion in children with relapsed clubfoot: a retrospective data analysis. *J Pediatr Orthop B*. 2017; 26(2):116-21. doi: 10.1097 /BPB.000000000 000 00390.
4. Adegbehingbe OO, Adetiloye AJ, Adewole L, Ajodo D, Bello N, Esan O, et al. Ponseti method treatment of neglected idiopathic clubfoot: Preliminary results of a multi-center study in Nigeria. *World J Orthop*. 2017; 8(8): 624-30.
5. Smythe T, Chandramohan D, Bruce J, Kuper H, Lavy C, Foster A. Results of clubfoot treatment after manipulation and casting using the Ponseti method: experience in Harare, Zimbabwe. *Trop Med Int Health*. 2016; 21(10):1311-1318. doi: 10.1111/tmi.12750.
6. Lourenco AF, Morcuende JA. Correction of neglected idiopathic club foot by the Ponseti method. *J Bone Joint Surg Br*. 2007; 89(3): 378-81.
7. Ippolito E, Fraracci L, Farsetti P, Di Mario M, Caterini R. The influence of treatment on the pathology of club foot. CT study at maturity. *J Bone Joint Surg Br*. 2004; 86(4): 574–80.
8. Bashi RH, Baghdadi T, Shirazi MR, Abdi R, Aslani L. Modified Ponseti method of treatment for correction of neglected clubfoot in older children and adolescents--a preliminary report. *J Pediatr Orthop B*. 2016; 25 (2): 99-103. doi: 10.1097/ BPB.0000000000000266.
9. Sinha A, Mehtani A, Sud A, Vijay V, Kumar N, Prakash J. Evaluation of Ponseti method in neglected clubfoot. *Indian J Orthop*. 2016; 50(5): 529-35. doi:10.4103/0019-5413.189597.
10. Khan SA, Kummar A. Ponseti's manipulation in neglected clubfoot in children more than 7 years of age: a prospective evaluation of 25 feet with long-term follow-up. *J Pediatr Orthop B*. 2010; 19 (5):385-9. doi: 10.1097/BPB.0b013e3283387cc8.
11. Faizan M, Jilani LZ, Abbas M, Zahid M, Asif N. Management of Idiopathic Clubfoot by Ponseti Technique in Children Presenting After One Year of Age. *J Foot Ankle Surg*. 2015; 54(5):967-72. doi: 10.1053/j.jfas.2014.05.009.
12. Dobbs MB, Nunley R, Schoenecker PL. Long-term follow-up of patients with clubfeet

- treated with extensive soft-tissue release. J Bone Joint Surg Am. 2006; 88(5): 986–96.
13. Anisi CO, Asuquo JE, Abang IE, Eyong ME, Osakwe OG, Ngim NE. The role of Pirani scoring in predicting the frequency of casting and the need for percutaneous Achilles tenotomy in the treatment of idiopathic clubfoot using the Ponseti method. Paediatr Orthop Relat Sci. 2017; 3(2): 55-9. doi: 10.4103/pors.pors\_8\_17.
14. Mehtani A, Prakash J, Vijay V, Kumar N, Sinha A. Modified Ponseti technique for management of neglected clubfeet. J Pediatr Orthop B. 2018; 27(1): 61-6. doi: 10.1097/BPB.0000000000000450.
15. Ayana B, Klungsoyr PJ, Good results after Ponseti treatment for neglected congenital clubfoot in Ethiopia: a prospective study of 22 children (32 feet) from 2 to 10 years of age. Acta Orthop. 2014; 85(6): 641-5. doi: 10.3109/17453674.2014.957085.
16. Abdelgawad AA, Lehman WB, van Bosse HJ, Scher DM, Sala DA. Treatment of idiopathic clubfoot using the Ponseti method: minimum 2-year follow-up. J Pediatr Orthop B. 2007; 16(2):98–105.



*AUTHOR AFFILIATION:*

**Dr. Muhammad Jamil** (*Corresponding Author*)

Assistant Professor  
Dow University of Health Sciences & Civil Hospital  
Karachi, Sindh-Pakistan.  
E-mail: jamil\_riaz@hotmail.com

**Dr. Adeel Ahmed Siddiqui**

Assistant Professor  
Dow University of Health Sciences & Civil Hospital  
Karachi, Sindh-Pakistan.

**Dr. Kashif Mahmood Khan**

Associate Professor  
Jinnah Postgraduate Medical Centre Karachi, Sindh-Pakistan.

**Dr. Jagdesh Kumar**

Assistant Professor  
Dow University of Health Sciences & Civil Hospital  
Karachi, Sindh-Pakistan.

**Dr. Muhammad Soughat Katto**

Assistant Professor  
Dow University of Health Sciences & Civil Hospital  
Karachi, Sindh-Pakistan.

**Dr. Malik Wasim Ahmed**

Assistant Professor  
Dow University of Health Sciences & Civil Hospital  
Karachi, Sindh-Pakistan.

**Dr. Mehtab Ahmed Pirwani**

Associate Professor  
Dow University of Health Sciences & Civil Hospital  
Karachi, Sindh-Pakistan.