

Hallervorden-Spatz Disease: Case Report based on Radiological and Genetic Analytical Findings

Ayesha Sardar, Muhammad Ashfaq, Bader-u-Nisa, Aijaz Ahmed, Hira Waseem

ABSTRACT

Hallervorden-Spatz disease is a rare disorder characterized by progressive extrapyramidal dysfunction and dementia. The disease can be familial or sporadic. *PKAN* is inherited recessively; it has been linked to chromosome 20. A mutation in the pantothenate kinase (*PANK-2*) gene has been described in patients with *PKAN*.

This case belongs to a 9-year-old girl who presented with dystonia for two years, speech disturbance and difficulty walking for the past four months. She was diagnosed based on MRI followed by genetic mutation analysis showing nonspecific *PANK-2* mutation. The genetic panel of both parents was sent, which was positive for a heterozygous mutation of the *PANK-2* gene in both parents. It is concluded that this variant is of uncertain significance.

Keywords: Dystonia, Hallervorden-Spatz disease, Tiger-eye appearance, Movement disorder, Pantothenate kinase two deficiency.

This article may be cited as: Sardar A, Ashfaq M, Nisa B, Ahmed A, Waseem H. Hallervorden-Spatz Disease: Case Report based on Radiological and Genetic Analytical Findings. *J Liaquat Uni Med Health Sci.* 2022;21(04):296-300.
doi: 10.22442/jlumhs.2022.00966. Epub 2022 November 23.

INTRODUCTION

Hallervorden-Spatz disease is a rare autosomal recessive syndrome due to the atypical mutation in the gene on chromosome 20, which encodes to make an enzyme called pantothenate kinase (*PANK*). The mutation in this gene is named *PANK-2*. This protein is present mainly in the brain's central nervous system and other organs, including the eyes, liver, etc. The protein 4-phosphopantetheine, produced by the enzyme Pantothenate kinase, has a vital role in developing and regulating brain biomarkers¹; lack of this enzyme affects the standard chemistry of the brain. Mutation influences the organ functions leading to amino acid modification (protein truncation); pantothenate is the prime element of vitamin B5; hence the defective gene influences vitamin B5 metabolism. This vitamin is crucial in producing coenzyme A in cells². The error disrupts the energy, affecting the metabolism of lipids. Subsequently, the irregular energy metabolism affects the cysteine deposition and forms complexes with iron. Cysteine-iron complex accelerates tissue oxidation leading to damage in basal ganglia. Patients with this syndrome usually show general neurodegenerative features like Parkinsonism, dystonia, and iron deposition inside the brain. Such patients are diagnosed by magnetic resonance imaging (MRI) and the levels of *Pantothenate kinase-2 protein*³.

Hallervorden-Spatz syndrome, also known as

Pantothenate kinase-associated neurodegeneration, was first described by two German scientists, Hallervorden and Spatz, in 1922⁴. Studies suggest this disease is rare, affecting one in a million individuals. However, the life expectancy rate is less than 15 years in most cases despite the timely treatment. Disease diagnosed in childhood is mostly on and off progressive, leading to the child's death in early adulthood. Generally, in this disorder, extrapyramidal symptoms are the elements for diagnosis. In this disease, research documented that the defective gene has the 7bp deletion leading to missense mutation and the formation of faulty proteins⁵. The common symptoms in such patients are oromandibular movement, dystonia, behavioural changes leading to dementia and retinal degeneration. The eye defect is due to iron accumulation in the globus pallidus, basal ganglia and substantia nigra resulting in retinal degeneration and loss of visual field⁶.

PKAN is classified into two: classical and atypical. In the classical type, the onset of the disease is in the first decade of life, while in atypical conditions, the beginning is in the second or third decade of life⁷. Commonly, the four significant disorders are noted in the classical *PKAN*. These are X-linked intellectual disability, Alpha-L fucosidosis, Leigh syndrome and Infantile neuroaxonal dystrophy. However, in the atypical *PKAN*, major disorders are early-onset Parkinson's disease, aceruloplasminemia, primary familial brain calcification, primary psychiatric disorders and neuroferritinopathy. Patients with the classical type of Hallervorden-Spatz disease are

Received: 24-05-2022
Revised: 19-10-2022
Accepted: 01-11-2022
Published Online: 23-11-2022

mostly confirmed with DNA analysis. However, atypical patients of this disorder typically have speech and movement disorders and are diagnosed with MRI and DNA analysis for the *PANK2* variant level⁹. In the classical state of disease, 4-phosphopantothenate levels and ferritin levels determine the cysteine-iron complex formation in the brain, which is the significant source of oxidative stress causing tissue damage that later influences motor neurons, leading to behavioural disorders⁹. Usually, in atypical cases, a high signal intensity region is seen in the globus pallidus because of iron deposition. In case of severity, along with iron deposits, axonal spheroids in the caudate nucleus, globus pallidus and substantia nigra are noted in the MRI scan. In such severity, the person usually loses their life within five years. The disease is progressive, and despite treatment, the photoreceptors reduce with time, which may cause blindness and disturb the control and balance of the body¹⁰.

CASE:

This is a case of a nine-year-old girl, the fifth child from a consanguineous marriage. She presented with dystonia since age two, speech disturbance, difficulty walking, and frequent falls for the last four months. The developmental milestones were achieved up to the age of two years, after which parents noticed abnormal body movements. It was characterized by abnormal stiffening and posturing of the body, but she could walk and do her home chores by herself. Her speech was delayed, and she could only speak words initially. These abnormal movements were progressive, followed by difficulty walking and frequent falls. However, she had no cognitive impairment. She had a history of multiple visits to a local physician and some spiritual healers. No other family members had similar or other movement disorders. Anthropometric examination revealed she had a height of 130cm and a weight of 26kg, which lay at the 15th percentile.

On presentation, she was vitally stable but had persistent dystonic movements characterized by generalized hypertonia, sustained contraction of muscles and repetitive abnormal movements of arms and neck with abnormal posturing. Her cognitive functions were intact. Her vision and hearing were expected, but she could only produce sounds and not speak appropriate words. Her sensory and motor systems were unchanged except for power which was 4/5 in all four limbs, and her gait was ataxic. The rest of the examination was unremarkable.

Along with the baseline workup, serum ceruloplasmin was sent for Wilson's disease, and EEG was done within normal limits. Eye examination was unremarkable. MRI brain with contrast showed abnormal signal intensity, with changes in the bilateral deep parietal basal ganglia region. These were hypointense on T2 weighted and flare images suggestive of the tiger eye sign seen in NBIA (neurodegenerative brain disorder with iron

accumulation) (Figure 1). To confirm our diagnosis genetic panel was sent to The Invitae Diagnostic Center for *PANK-2* mutation, which showed a nonspecific homozygous mutation of the *PANK-2* gene (Figure 2). The genetic panel of parents was done, which showed both parents have a heterozygous mutation for the said gene (Figure 3 A, B). Based on clinical presentation, MRI brain and *PANK-2* gene mutation, the patient was diagnosed with a Hallervorden-Spatz disease. She was kept on Tab trihexyphenidyl, Tab Tizanidine and Tab, and Tetrabenazine with follow-up advice. Speech therapy and exercise with an altered diet were advised to facilitate communication and functional skills.

FIGURE 1: TIGER EYE SIGN APPEARANCE IN MRI BRAIN IMAGING

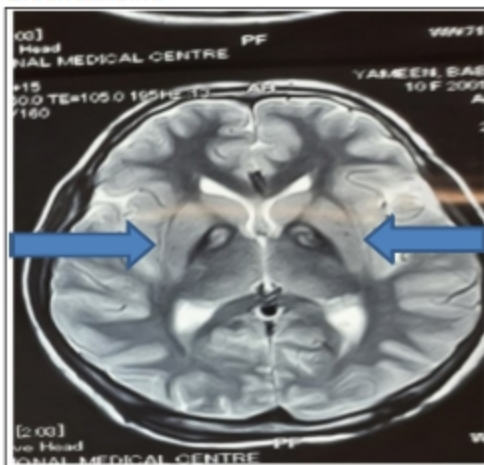


FIGURE 2: GENETIC PANEL FOR PANK-2 GENE IN THE PATIENT

INVITAE
NIVATA DIAGNOSTIC TESTING RESULTS

Patient Name: Aisha Hashmi
DOB: 11/03/2009
Sex: Female
Sample ID: T1836303
Sample Acquisition Date: 10/15/21

Reason for testing: Diagnostic test for personal history of disease
Test performed: Sequence analysis and deletion/duplication using whole exome based on the Invitae panel.
• NGS, sequencing with 150 bp read length

RESULT: UNCERTAIN

Variants of Uncertain Significance listed:

GENE	VARIANT	TISSUE	Variant Classification
PANK2	c.283G>C (p.G94S)	Neuronal	Uncertain Significance

About this test:
This diagnostic test evaluates 22 genes for variants (genetic changes) that are associated with genetic diseases. Diagnostic genetic testing, when combined with family history and other medical studies, helps provide insight into a patient's individual risk, carrier status, genetic diagnosis, and assist with the development of a personal care treatment and management strategy.

FIGURE III A: GENETIC PANEL OF THE MOTHER FOR THE PANK-2 GENE



FIGURE III B: GENETIC PANEL OF FATHER FOR PANK-2 GENE



RESULT

A diagnostic test for a personal history of the disease was done. Sequence analysis and deletion/duplication testing of the 20 genes were done that are listed. Neurodegeneration with Brain Iron Accumulation Panel was done. No pathogenic variants were found, but it was understood that variants change over time. The result was analyzed

and interpreted within the context of other laboratory results, clinical findings, and family history. Testing of parents for the variants was done, and two variants of uncertain significance (VUS) c.397A>C (p. Met133Leu) (homozygous) were identified in PANK-2. Given the finding, complementary family studies as a part of the VUS resolution program were also conducted.

Variant Details: PANK-2, Exon 1, c.397A>C (p. Met133Leu), homozygous, uncertain significance. Methionine was replaced with leucine at codon 133 of the PANK-2 protein (p. Met133Leu) as a sequence change. A slight physicochemical difference between methionine and leucine was found, and methionine residue was weakly conserved. The frequency of the data was considered unreliable since metrics indicated insufficient coverage. The variant was observed with pantothenate kinase-a associated neurodegeneration. It was concluded that the effect of missense changes on protein structure and function (SIFT, PolyPhen-2, Align-GVGD) was likely to be tolerated, but this could not be confirmed with data or any other published studies. Therefore their clinical significance was considered insufficient. However, the author believes this may be a clinically significant amino acid residue since this variant disrupts the p. Met.133 amino acid residue in PANK-2. Other variants that disrupt this residue have been observed in individuals with PANK-2-related conditions^{11,12}.

The following is a list of all genes analyzed for the patient. Benign and likely benign variants have not been investigated but were available as a part of the result of the study. (Table 1)

TABLE 1: GENETIC ANALYSIS OF THE PATIENT SHOWING MUTATIONS IN OUR PATIENT AND SHOWING ALL GENES ANALYZED

GENE	TRANSCRIPT
AP4M1	NM_004722.3
ATP13A2	NM_022089.3
C19orf12	NM_01031726.3
COASY	NM_025233.6
CP	NM_000096.3
CRAT	NM_000755.3
DCAF17	NM_025000.3
FA2H	NM_024306.4
FTL	NM_000146.3
FUCA1	NM_000147.4
GJA1	NM_000165.4
GTPBP2	NM_019096.4
KIF1A	NM_004321.6
PANK2	NM_153638.2
PLA2G6	NM_003560.2
REPS1	NM_001286611.1
SCP2	NM_002979.4
SLC25A42	NM_178526.4
SQSTM1	NM_003900.4
WDR45	NM_007075.3

DISCUSSION

Medicinal treatment is given, which must pass through the blood-brain barrier and cellular membranes. Medication includes dopaminergic agonists; anticholinergic agonists are used to curing rigidity and spasticity. In this study, the patients were given Tab trihexyphenidyl, Tab Tizanidine and Tab. Tetrabenazine and was advised for follow-up. Furthermore, in releasing the behavioural alterations, the aid of a multidisciplinary team is used for speech therapy, exercise with altered diet and functional skills¹⁵. Taking advantage of professional healthcare providers is considered necessary because dementia or other neurodegenerative advancements in the brain does not respond to treatment¹⁴. In this study, the patient was also advised of these considerations. In the family of an affected individual, parents must get into the neurologic evaluation of the siblings of the proband like MRI, which helps in the carrier status in the family. In addition, genetic counselling must be taken in family planning by discussing the risks of reproductive options. To date, different tests are available concerning the present prenatal testing of gene diagnosis, particularly for PANK-2 before pregnancy, to determine the potential risk to offspring¹⁵. Generally, prenatal testing is done within 15 to 18 weeks of gestation, and the DNA is extracted from fetal cells in amniocentesis. If the sample is needed earlier, chorionic villus testing is performed within 10 to 12 weeks of gestation to determine mutation. The patient's parents were included in this case study's tests and clinical evaluation. To date, this has been investigated that at the time of conception, each sibling has a 25% chance of being symptomatically diseased, a 50 % chance of being a carrier, and a 25% chance of being unaffected¹⁶.

CONCLUSION

Our patient has classical clinical findings of Hallervorden Spatz disease, and investigations also support our diagnosis; however, genetic testing showing the variant is of uncertain significance. But in future, this genetic mutation may be associated with the diagnosis of Hallervorden Spatz disease, for which further studies are needed.

Conflict of Interest: The authors have no conflict of interest to declare.

Financial Disclosure / Grant Approval: No funding agency was used for this research.

Data Sharing Statement: The data supporting this study's findings are available on request from the corresponding author. The data are not publicly available due or ethical restrictions.

AUTHOR CONTRIBUTIONS

Sardar A: Manuscript writing

Ashfaq M: Supervision of case and manuscript process
Bader-u-nisa: Manuscript writing

Ahmed A: Diagnosis of Case

Waseem H: Critical checking for final approval

REFERENCES

- Patil DD, Pujalwar S, Singh YD. Hallervorden Spatz Disease. *J Evol Med Dent Sci.* 2018; 7(52): 5570-3.
- Asadi S. The Role of Genetic Mutations in Gene PANK2 on Hallervorden-Spatz Syndrome. *Biomed J Sci Tech Res.* 2019; 22(3): 16684-7. doi: 10.26717/BJSTR.2019.22.003753.
- Voges L, Kupsch A. Renaming of Hallervorden-Spatz disease: the second man behind the name of the disease. *J Neural Transm(Vienna).* 2021; 128(11): 1635-40. doi: 10.1007/s00702-021-02408-x. Epub 2021 Oct 16.
- da Rocha LD, de Sousa MN, Quemelo PR, Lucena PA. Hallervorden-Spatz Syndrome: Case Report of a Typical Form. *Ann Clin Case Stud.* 2021; 3(2): 25-26.
- Prasadani TM. 1813 Progressive dystonia and neurodegeneration with eye of the tiger sign in MRI brain-hallervorden-SPATZ syndrome. *Arch Dis Childhood.* 2021; 106(Suppl 1): A499-A500. doi: 10.1136/archdischild-2021-rcpch.867.
- Walker RH, Hegele RA, Danek A. Comment on "A New Allelic Variant in the PANK2 Gene in a Patient with Incomplete HARP Syndrome". *J Mov Disord.* 2021; 14(3): 254-5. doi: 10.14802/jmd.20145.
- Svetel M, Dragašević N, Petrović I, Novaković I, Tomić A, Kresojević N et al. NBIA Syndromes: A Step Forward from the Previous Knowledge. *Neurol India.* 2021; 69(5): 1380-88. doi: 10.4103/0028-3886.329603.
- Koc D. Pantothenate kinase associated neurodegeneration. *Orphan Anesthesia.* 2020; 61 (Suppl 2): S392-8. doi: 10.19224/ai2020.s392.
- Werning M, Dobretzberger V, Brenner M, Müllner EW, Mlynek G, Djinic-Carugo K et al. A Potential Citrate Shunt in Erythrocytes of PKAN Patients Caused by Mutations in Pantothenate Kinase 2. *Biomolecules.* 2022; 12(2): 325. doi: 10.3390/biom12020325.
- Pan S, Zhu C. Atypical pantothenate kinase-associated neurodegeneration with PANK2 mutations: clinical description and a review of the literature. *Neurocase.* 2020; 26(3): 175-82. Epub 2020 Apr 20. doi: 10.1080/13554794.2020.1752739.
- Ma LY, Wang L, Yang YM, Lu Y, Cheng FB, Wan XH. Novel gene mutations and clinical features in patients with pantothenate kinase-associated neurodegeneration. *Clin Genet.* 2015; 87(1): 93-5. Epub 2014 Apr 1. doi: 10.1111/cge.12341.
- Zhou J, He J, Kou LP, Feng HC, Deng YH, Zhang ZB et al. Phenotypic and genotypic features of twenty children with classic pantothenate kinase-

- associated neurodegeneration. Zhonghua Er Ke Za Zhi. 2017 Sep 2; 55(9): 678-682. Chinese. doi: 10.3760/cma.j.issn.0578-1310.2017.09.011.
13. Munshi MI, Yao SJ, Mamoun CB. Redesigning therapies for pantothenate kinase-associated neurodegeneration. J Biol Chem. 2022: 101577. doi: 10.1016/j.jbc.2022.101577.
 14. Iankova V, Karin I, Klopstock T, Schneider SA. Emerging disease-modifying therapies in Neurodegeneration with Brain Iron Accumulation (NBIA) disorders. Front Neurol. 2021; 12. doi: 10.3389/fneur.2021.629414
 15. Bhardwaj NK, Gowda VK, Saini J, Sardesai AV, Santhoshkumar R, Mahadevan A. Neurodegeneration with brain iron accumulation: Characterization of clinical, radiological, and genetic features of pediatric patients from Southern India. Brain Dev. 2021; 43(10): 1013-22. Epub 2021 Jul 14. doi: 10.1016/j.braindev.2021.06.010.
 16. Spaul RV, Soo AK, Hogarth P, Hayflick SJ, Kurian MA. Towards Precision Therapies for Inherited Disorders of Neurodegeneration with Brain Iron Accumulation. Tremor Other Hyperkinet Mov (N Y). 2021; 11: 51. doi: 10.5334/tohm.661.



AUTHOR AFFILIATION:

Dr. Ayesha Sardar

Registrar (Pediatric Medicine)
National Institute of Child Health
Karachi, Sindh-Pakistan.

Dr. Muhammad Ashfaq

Assistant Professor (Pediatric Medicine)
National Institute of Child Health
Karachi, Sindh-Pakistan.

Dr. Bader-U-Nisa

Assistant Professor (Pediatric Medicine)
National Institute of Child Health
Karachi, Sindh-Pakistan.

Dr. Aljaz Ahmed (*Corresponding Author*)

Senior Registrar (Pediatric Medicine)
National Institute of Child Health
Karachi, Sindh-Pakistan.

Dr. Hira Waseem

Senior Registrar (Pediatric Medicine)
National Institute of Child Health
Karachi, Sindh-Pakistan.



2022 © This is an Open Access article distributed under the terms of the Creative Commons Attribution – Non-Commercial 4.0 International License, which permits unrestricted use, distribution & reproduction in any medium provided that the original work is cited properly.