

Evaluation of Complex Tibial Pilon Fractures Treated with Ilizarov External Fixator

Mehtab Ahmed Pirwani, Jagdish Kumar, Muhammad Soughat Katto, Nusrat Rasheed, Badaruddin Sahito, Ghulam Mustafa Kiam Khani

ABSTRACT

BACKGROUND: Ilizarov external fixator is now considered a suitable alternate treatment modality for treatment of complex tibial pilon fractures with questionable soft tissue integrity; it allows early weight bearing without jeopardizing the fracture stability and bone healing.

OBJECTIVE: The purpose of study was to evaluate clinico-radiological outcome and morbidity of the Ilizarov external fixator used for fixation of complex tibial pilon fractures.

METHODS: This retrospective analytic cross-sectional study was conducted at Orthopaedic Surgery department, Dow Medical College / Dr Ruth Pfau Civil Hospital Karachi, from June 2014 to May 2017. A total of 17 consecutive patients with complex tibial pilon fracture (AO type 43C) operated with Ilizarov external fixator technique were evaluated functionally by using the American Orthopaedic Foot and Ankle Society scoring system (AOFAS) and radio-logicaly for fracture union (delayed, nonunion) after a mean followup of 6 months. Post-surgical complications were noted. Polytrauma patients with additional fracture in pelvis and spine, pathological fracture, delayed presentation (> 2 weeks) and AO type 43A & B were excluded from the study.

RESULTS: Total 17 patients (29.4% female and 70.6% male) with mean age 28 years (range, 17 - 48 years) were analyzed in this study. 11 (64.7%) fractures had left ankle while 6 (35.2%) fractures had right ankle involvement. The minimum follow-up was 3 months after complete frame removal. According to AO classification, C1 in 9 cases, C2 in 3 cases and C3 in 5 cases. All fractures were united in average 14.6 weeks (range 10-28 weeks). According to AOFAS scoring system, the final functional results were excellent in 5 (29.4%), good in 10 (58.8%) and fair in 2 (11.7%). There were 82.3% pin tract infections in this series. Ankle joint arthritis was noted in five patients. We had no instance of postoperative deep infection and neurovascular complications due to Ilizarov fixation.

CONCLUSIONS: The Ilizarov ring fixator is a minimal invasive procedure that offers biological advantages and is a suitable alternate for treatment of complex tibial pilon fractures with questionable soft tissue integrity providing fracture healing, rapid functional recovery, and avoidance of major complications associated with extensive operative dissection needed with plate osteosynthesis.

KEY WORDS: Tibial pilon fractures, Ilizarov, External fixator, Minimal invasive

This article may be cited as: Pirwani MA, Kumar J, Katto MS, Rasheed N, Sahito B, Kiam Khani GM. Evaluation of Complex Tibial Pilon Fractures Treated with Ilizarov External Fixator. J Liaquat Uni Med Health Sci. 2018;17(02):80-5. doi: 10.22442/jlumhs.181720555

INTRODUCTION

Pilon or plafond fracture of the distal tibia in adult is a devastating injury, as they are typically intra-articular and associated with osseous comminution and extensive soft tissue insult. If it is not treated properly; it may even end up in having permanent disability. These fractures frequently result from high-energy axial impact and estimated to comprise less than 1% of all lower extremity fractures and 3% to 10% of all tibia fractures^{1,2}.

The main objectives of treatment are to restore the articular congruency and mechanical alignment with minimal disruption of soft tissue envelope. These goals should be accomplished with a technique that must be truly minimally invasive. Osteosynthesis with

plate and screws permit an exact reconstruction of an articular surface but despite the advent of locked plating and "minimally invasive" surgical techniques, often associated with an un-acceptably high rate of deep infections, wound dehiscence and soft tissue problems. Once complications set in, patients will have longer length of stay in the hospital. Often the patient may end up in having amputation after multiple operations and treatment attempts³⁻⁶.

To consider these drawbacks we are routinely using Ilizarov external fixator at our institution for complex pilon fractures of distal tibia in adult.

The advantages of Ilizarov external fixators are minimal invasive fixation by thin wires, strong circumferential construct giving multi-planar stability,

inter-fragmentary compression by use of olive wires and axial stability by threaded rods. Applications of Ilizarov fixators do not cause any significant additional trauma to the soft tissues because of its thin wire fixation. This instrument allows for axial micro-motion due to the use of flexible wires and also helps in early mobilization and weight bearing because of its three-dimensional stability⁷.

Recently several studies have evaluated its outcome and reported decreased complication rates in complex pilon fracture in comparison with other methods of fixation^{2,7-12}.

Hence to evaluate clinico-radiological outcome and its morbidity, the current study is being carried out.

METHODOLOGY

This retrospective analytic cross-sectional study was conducted in the Orthopaedic Surgery department of Dow Medical College / Dr Ruth Pfau Civil Hospital Karachi, from June 2014 to May 2017. This study evaluated retrospectively via medical record of 17 consecutive patients of complex tibial pilon fractures (AO type 43C) who underwent closed reduction and percutaneous fixation with Ilizarov external fixator technique. Polytrauma patients with additional fracture in pelvis and spine, pathological fracture, delayed presentation (> 2 weeks) and AO type 43A & B were excluded from the study.

AO classification system was used retrospectively to describe tibial pilon fractures (TPF)¹³. Gustilo and Anderson classification¹⁴ was used for open fracture and Tschern and Oestern classification¹⁵ of soft tissue injury was used for closed fractures.

Sample technique

Non-probability –purposive sampling technique were used to select 17 patients, who sustained complex tibial pilon fractures requiring surgery.

Sample size calculation

Determination of sample size was based on an epidemiological study, where tibial pilon fractures in adult comprise less than 1% of all lower extremity fractures and 3% to 10% of all tibia fractures.

Using Fishers' formula

$$n = Z^2 PQ / D^2$$

Where

n is the estimated sample size.

Z² is the score of confidence interval at 95% and is 1.962.

P is the prevalence in this case at 1% and Q is 1 – P.

D² is the degree of error, which is 0.052

Therefore

$$n = 1.962 \times 0.01 (1 - 0.01) / 0.052$$

$$n = 16 \text{ patients}$$

Data collection and statistical analysis

The required information was gathered through a

review of medical record, operative notes and radiographs on a structured proforma designed for the study. The data was analyzed using SPSS version 19 and descriptive statistics for sample variables presented in form of tables and graphs.

Surgical procedure & post-operative management

After the initial assessment and management of the trauma patient in the emergency room, the leg was realigned with manual traction and support, and placed in a well-padded splint. The risks and benefits of operative procedure were explained in detail and written informed consent was taken. After medical assessment, if patient is deemed medically stable, he or she underwent for surgery on elective list. Preoperative antibiotics for surgical prophylaxis were given. Surgery was done under spinal and / or general anesthesia with a patient in supine position on a radiolucent traction table, under C-arm guidance.

After scrubbing and draping of extremity, the first step was the fibular length realignment either by a closed / open rush nail or 2.5 mm K-wire, to help restore the lateral pillar. Second step was to place the leg on continuous longitudinal traction with a half calcaneal ring attached to a traction table external apparatus for distraction and reduction of fracture fragments with ligamentotaxis.

Four ring construct spanning the ankle was used in all the cases. Two-rings were placed over the proximal tibial fragment keeping the limb in the center. The first Ilizarov ring was positioned at the level of fibular head parallel to the knee joint. The second ring was positioned just 2cm proximal to the fracture. An advanced hybrid fixation using 5mm half pins and 1.8mm wires were used in upper two rings. The third ring was positioned just above the ankle joint line. If distraction of fracture fragments and fibular fixation did not lead to acceptable anatomical repositioning, the articular surfaces were reconstructed with percutaneous inserted reduction forceps and / or with threaded pin or K-wires as joystick. Once the fracture has been reduced satisfactorily under C-arm, the bone fragments were stabilized with thin wires and olive wires, tensioned and fixed to the third ring.

The fourth (distal- most) calcaneal half ring, to accommodate the foot anteriorly, was placed at the level of the calcaneal tuberosity, after removing previous half calcaneal ring placed for traction and was stabilized with 2 olive wires / 2 half pins.

Mostly, inter-fragmentary compression of large articular fragments and the syndesmosis were achieved using olive wires. In most cases, 1 half pin and 2 wires were inserted to the proximal fragment and 3 / 4 wires were inserted to the distal fragment. Bone grafts were not used. A single surgeon performed the operations. Postoperative pin site

dressing were done using the Kurgan Protocol¹⁶.

Rehabilitation protocol and outcome assessment

Intravenous antibiotics were infused for 2 - 3 days, followed by oral medications for further 5 -7 days to prevent infection. All patients followed the same rehabilitation protocol during hospitalization. Supervised therapy for sitting, standing and weight bearing ambulation as tolerated, depending on the general condition of the patient was begun from the very first post-operative day using a walker. Sutures were removed in two weeks. The calcaneus half-ring was removed after 6 / 8 weeks to allow early mobilization of ankle.

Any displacement, angulation or mal alignment discovered postoperatively or during follow up visits was readily corrected by readjustment. Complete Ilizarov Fixators were removed after clinical and radiographic evidence of fracture healing around 16-20 weeks.

Patients were followed up at 2, 4, 8, 12 weeks and 6 months postoperatively. At the last visit, the patients were evaluated clinically for functional outcome by using the American Orthopaedic Foot and Ankle Society (AOFAS) scoring system¹⁷ and radiologically for fracture union (delayed, nonunion). Typical post surgical complications were noted (i.e., pin tract infection, neuro-vascular injuries, nonunion, mal union and ankle arthritis).

The fractures were regarded as healed when radiologically, showed a bridging callus in three of four cortices in anteroposterior and lateral views and clinically, when the fracture was stable and nontender at the fracture site on manual stress and the patients were able to walk without pain after the connecting rods had been removed¹⁸.

Nonunion was defined as failure of clinical or radiological union more than six months after the initial operation¹⁹. Malunion was defined as $> 10^\circ$ of angulation in any direction at the time of union¹². Pin-track infection was diagnosed by presence of purulent discharge, skin erythema and radiological evidence of *wire* or *half-pin loosening* and the Checketts RG classification²⁰ was used to report pin tract infections. Ankle arthritis was diagnosed by painful restriction of all movements with or without crepitus with radiological evidence of reduced joint space²¹.

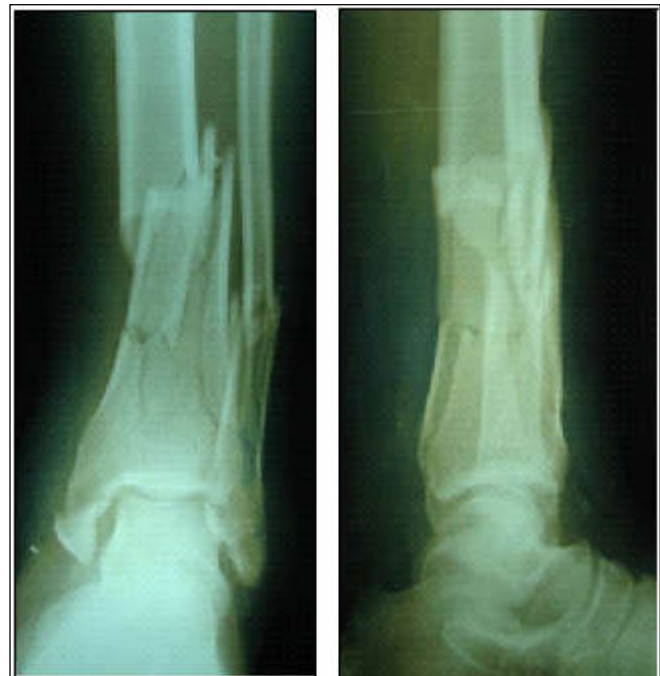RESULTS

Total 17 patients with mean age 28 years (range, 17-48 years) were analyzed in this study. Female were 5(29.4%) and male were 12(70.6%). 11 (64.7%) fractures had left ankle while 6 (35.2%) fractures had right ankle involvement. Mean delay between the trauma and Ilizarov external fixation was 6.8 days (range 3 – 14 days). The minimum follow-up was 3

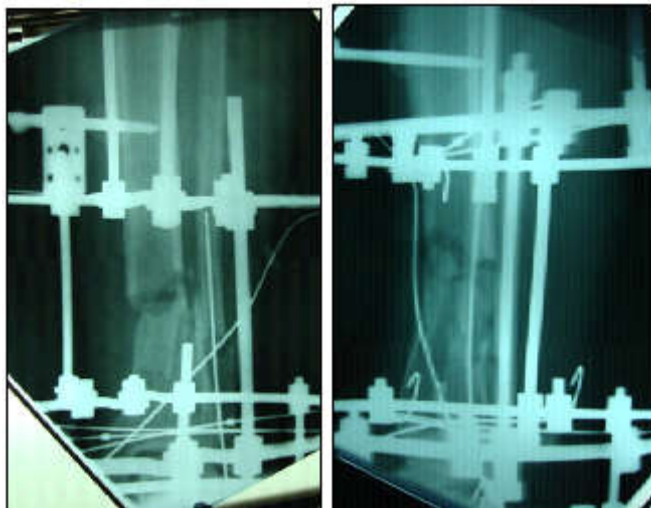
months after complete frame removal (average, 8 months; range, 3 to 18 months). According to the Gustilo and Anderson classification, 3 patients had a grade I open fracture while the remaining 14 patients had closed fractures; according to the Tschernke and Gotzen classification of soft tissue injuries, 5 patients had grade II and 9 patients grade III injury. According to the AO classification, 9 fractures graded as type 43-C1, 3 as 43-C2 and 5 as 43-C3. All patients had an associated fibular fracture; all were fixed with closed 2.5mm k-wire. 10 patients were involved in a road traffic accident, 6 fell from a height, and two were crush injury. All fractures were united in average 14.6 weeks (range 10-28 weeks); secondary bone grafting was not needed. Delayed and non-union were not noted. According to AOFAS scoring system, the final functional results were excellent in 5 (29.4%), good in 10 (58.8%) and fair in 2 (11.7%). There were 14 (82.3%) pin tract infection in this series; Most pin-tract infections settled well with regular pin cleaning and oral antibiotics but in eight cases affected loose pins and wires were exchanged or removed as fracture healing progressed. We had no instance of postoperative deep infection and neurovascular complications due to Ilizarov fixation. Ankle joint arthritis was noted in five patients. However, despite radiographic degenerative changes, no patients to date had required an ankle arthrodesis. All of them were managed with non-steroidal anti-inflammatory drugs (NSAIDs).

PRE-OPERATIVE X-RAY:

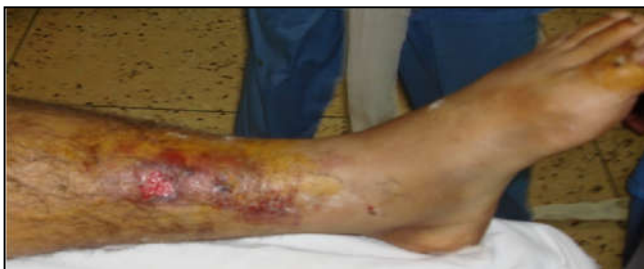A- AP VIEW B- LATERAL VIEW



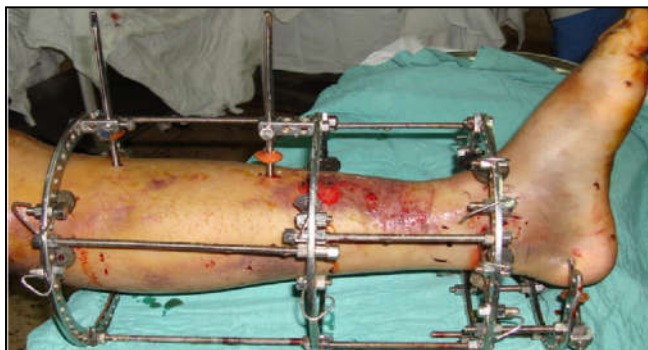POST-OPERATIVE X-RAY: AP AND LATERAL VIEW SHOWING FIXATION WITH ILIZAROV EXTERNAL FIXATOR



PRE-OP IMAGE SHOWING SOFT TISSUE INVOLVEMENT



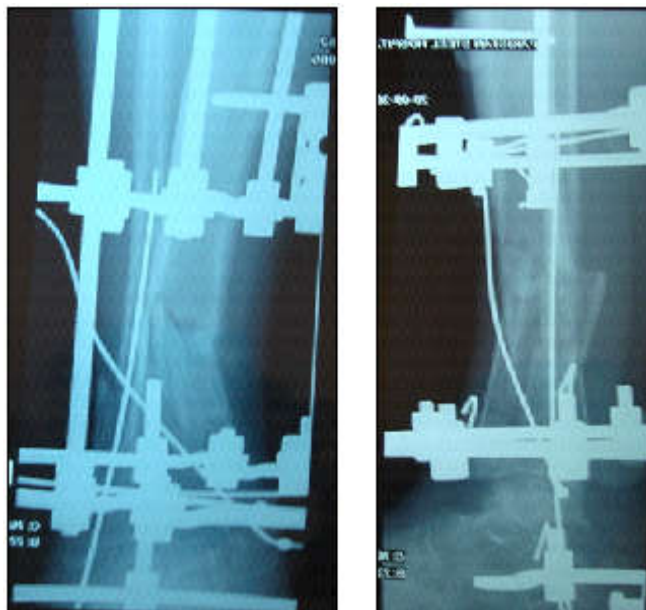
POST-OPERATIVE IMAGE SHOWING ILIZAROV EXTERNAL FIXATOR



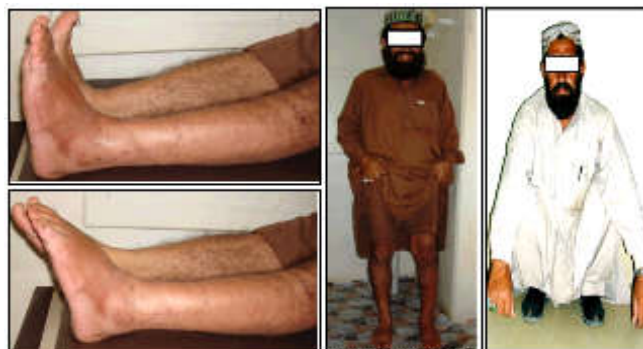DISCUSSION

High-energy tibial pilon or plafond fractures are notorious injuries often associated with severe soft tissue damage and high rate of unforgiving wound complications following formal open reduction and internal fixation (ORIF) with plate osteosynthesis³⁻⁶. The main objectives of treatment are to recreate joint surfaces and to maintain bone axis, rotation and length to enable early postoperative mobilization while

POSTOPERATIVE X-RAY AP AND LATERAL VIEW SHOWING CALLUS FORMATION 8 WEEK AFTER SURGERY



FUNCTIONAL OUTCOME AFTER 1 YEAR OF SURGERY



minimizing soft tissue complications. These goals should be accomplished with a technique that must be truly minimally invasive.

Recently several authors have supported Ilizarov circular fixator as an alternative treatment option for complex pilon fractures with compromise soft tissue, it provides a method for closed reduction and fixation that does not necessitate excessive soft tissue stripping and allows early weight bearing without jeopardizing the fracture stability and bone healing^{2,7-12}. Kholeif A et al did a study on 15 patients with comminuted tibial pilon fractures treated with Ilizarov ring fixator. He reported 66% excellent to good functional results and concluded that Ilizarov fixator is a reliable method for stabilization and healing of high energy distal tibia intra-articular fractures with acceptable frequency of soft tissue complications⁸.

Patra et al did a comparative study on 46 patients with pilon fractures treated with either internal fixation or Ilizarov external fixator and concluded that 'compared with formal open reduction and plate fixation, Ilizarov method resulted in fewer complications and better ankle function⁷.

Loviseti et al did a study on 30 cases of AO type 43 C tibial pilon fractures treated with Ilizarov methods. He reported excellent and good restoration of articular structure in 27 cases and good clinical results in 15 cases. Union achieved in all cases. he had no case of pseudarthrosis or deep infection⁹.

Vidyadhara et al did a study on 21 patients of high energy tibial pilon fractures treated with Ilizarov ring fixator. He reported 76% excellent to good results. He had no long-term problems with fracture union and no patient required an ankle arthrodesis¹⁰.

Jajec M et al did a study on 15 patients of displaced tibial pilon fractures treated with external ring fixator, and reported 100% excellent to good results. In this study he observed that 'external fixation with open reduction and limited internal osteosynthesis, with or without bone grafting, could be an option in the management of displaced multi-fragmentary pilon fractures with soft tissue injury. It was followed by significantly less complications with better functional results compared to open reduction and internal plate fixation¹¹.

In our study, we also found similar findings; we achieved union in all cases at average 14.6 weeks (range 10-28 weeks); secondary bone grafting was not needed. Non-union was not noted. At final follow-up, in our study according to American Orthopaedic Foot and Ankle Society scoring system 88.2% of patients had excellent to good functional outcome. The complications encountered in the operative treatment of distal tibia pilon fractures due to Ilizarov wires as reported by various authors are pin tract infections, neuro-vascular injuries and tendon or muscle impingement⁷⁻¹². The other postop complications are obstruction to joint motion, ankle arthritis, axial deviation and malunion. In our study, 82.3% of cases had pin tract infection; most pin-tract infections settled well with regular pin cleaning and oral antibiotics but in eight cases involved pins were removed as fracture healing progressed. We had no instance of postoperative deep infection and neurovascular complications due to Ilizarov fixation. Ankle joint arthritis was noted in five patients. However, despite radiographic degenerative changes, no patients to date had required an ankle arthrodesis. All of them were managed with NSAIDs, if needed. Hence, the results in this study were similar to the results noted in most other studies.

CONCLUSION

The Ilizarov ring fixator is a minimal invasive procedure that offers biological advantages and is a suitable alternate to non-operative options or internal fixation for treatment of complex tibial pilon fractures with questionable soft tissue integrity providing fracture healing, rapid functional recovery, and avoidance of major complications associated with extensive operative dissection needed with plate osteosynthesis.

Despite the limitations of this study, including its small sample size and short follow-up period, we believe that it would contribute to the evaluation of benefits expected from the Ilizarov ring Fixator for surgeons treating pilon fractures of ankle.

Conflict of interest = No

REFERENCES

1. Reid JS. Pilon fractures update. *Current Orthopaedic practice*. 2009; 20(5):527-33. doi: 10.1097/BCO.0b013e3181b64ea7
2. Jajec M, Starešinić M, Čuljak V, Vrgoč G, Šebečić B. The role of external fixation in displaced pilon fractures of distal tibia. *Acta Clin Croat* 2013; 52: 478-84.
3. McFerran MA, Smith SW, Boulas HJ, Schwartz HS. Complications encountered in the treatment of pilon fractures. *J Orthop Trauma* 1992; 6(2):195-200.
4. Rüedi TP, Allgöwer M. The operative treatment of intraarticular fractures of the lower end of the tibia. *Clin Orthop Relat Res* 1979; 138:105-10.
5. Ovadia DN, Beals RK. Fractures of the tibial plafond. *J Bone Joint Surg*. 1986; 68(4):453-51.
6. Teeny S, Wiss DA, Hathaway R, Sarmiento A. Tibial plafond fractures: errors, complication, and pitfalls in operative treatment. *Orthop Trans* 1990; 14(2): 265.
7. Patra SR, Kisan D, Panigrahi NK, Das DS, Manoj M, Samant S, et al. Operative outcome of high energy pilon fractures: a retrospective comparison between internal fixation and Ilizarov external fixation. *Int J Res Orthop* 2017; 3(2):177 - 84. DOI: <http://dx.doi.org/10.18203/issn.2455-4510.IntJResOrthop20170078>
8. Kholeif A. Management of comminuted tibial pilon fractures by Ilizarov external fixation. *Med J Cairo Univ* 2009; 77(4):101-8.
9. Loviseti G, Agus MA, Pace F, Capitani D, Sala F: Management of distal tibial intra-articular fractures with circular external fixation. *Strategies. Trauma Limb Reconstr* 2009, 4(1):1-6.
10. Vidyadhara S, Rao SK. Ilizarov treatment of complex tibial pilon fractures. *Int Orthop* 2006; 30

- (2):113-7.
11. VillaseñorVillaseñor LE, Olea Leyva MA, Rodríguez Flores R, Hernández López JL. Clinical outcome of a bilateral tibial pylon fracture treated with a minimally invasive technique. *Acta Ortop Mex* 2009; 23(3):163-6.
 12. Kapoor SK, Kataria H, Patra SR, Boruah T. Capsuloligamentotaxis and definitive fixation by an ankle-spanning Ilizarov fixator in high-energy pilon fractures. *J Bone Joint Surg Br* 2010; 92(8):1100-6. doi: 10.1302/0301-620X.92B8.23602.
 13. Muller ME, Nazarian S, Koch P, Schatzker J. *The Comprehensive Classification of Fractures of Long Bones*. Berlin, Germany: Springer-Verlag; 1990.
 14. Gustilo RB, and Anderson JT. Prevention of infection in the treatment of one thousand and twenty-five open fractures of long bones: retrospective and prospective analyses. *J Bone Joint Surg Am* 1976; 58(4): 453-8.
 15. Tscherne H, Gotzen L, editors. , eds. *Fractures with Soft Tissue Injuries (German)*. Telger TC (trans.). Berlin, Germany: Springer-Verlag; 1984:1-9.
 16. Davies R, Holt N, Nayagam S. The care of pin sites with external fixation. *J Bone Joint Surg Br* 2005; 87(5):716 - 19.
 17. Kitaoka HB, Alexander IJ, Adelaar RS, Nunley JA, Myerson MS, Sanders M. Clinical rating systems for the ankle-hindfoot, midfoot, hallux and lesser toes. *Foot Ankle Int* 1994;15(7):349-53.
 18. Ramos T, Karlsson J, Eriksson BI, Nistor L. Treatment of distal tibial fractures with the Ilizarov external fixator - a prospective observational study in 39 consecutive patients. *BMC Musculoskelet Disord* 2013; 14:30. doi: 10.1186/1471-2474-14-30.
 19. Wyrsh B, McFerran MA, McAndrew M, et al. Operative treatment of fractures of the tibial plafond: a randomized, prospective study. *J Bone Joint Surg Am* 1996; 78(11):1646-57.
 20. Checketts RG, MacEachern AG, Otterburn M (2000) Pin Track Infection and the Principles of Pin Site Care. In: De Bastiani G., Apley A.G., Goldberg A. (eds) *Orthofix External Fixation in Trauma and Orthopaedics*. Springer, London
 21. Marsh JL, Weigel DP, Dirschl DR. Tibial plafond fractures. How do these ankles function over time. *J. Bone Joint Surg Am* 2003; 85-A(2): 287-94.



AUTHOR AFFILIATION:

Dr. Mehtab Ahmed Pirwani (*Corresponding Author*)

Associate Professor
D.U.H.S & Civil Hospital Karachi, Sindh-Pakistan.
E-mail: mehtabpirwani@gmail.com

Dr. Jagdesh Kumar

Assistant Professor
D.U.H.S & Civil Hospital Karachi, Sindh-Pakistan.

Dr. Muhammad Soughat Katto

Assistant Professor
D.U.H.S & Civil Hospital Karachi, Sindh-Pakistan.

Dr. Nusrat Rasheed

Assistant Professor
D.U.H.S & Civil Hospital Karachi, Sindh-Pakistan.

Dr. Badaruddin Sahito

Assistant Professor
D.U.H.S & Civil Hospital Karachi, Sindh-Pakistan.

Dr. Ghulam Mustafa Kaimkhani

Professor
D.U.H.S & Civil Hospital Karachi, Sindh-Pakistan.